

“Treatment of Acute Hemoptysis by Bronchial Artery Embolization with the Liquid Embolic Agent Ethylene Vinyl Alcohol Copolymer”

Ayx I et al, 2017



Highlights:

1. Two center, retrospective study
2. 34 patients
3. Bronchial artery embolization with Onyx™
4. Follow-up mean: 8.8 months (71% patients)
5. Technical and clinical success in 94% of cases; 9% complications; 15% hemoptysis recurrence.

Background

- Bronchial artery embolization (BAE) is the primary treatment for acute hemoptysis (expectoration of blood) in patients who are not technically treatable by bronchoscopy or surgical treatment.
- For embolization of bronchial arteries, various embolic materials have been used, including Onyx™ Liquid Embolic System (LES) (Medtronic, Tolochenaz, Switzerland).
- It has been previously showed the technical feasibility and safety of using Onyx™ in the embolization of bronchial and pulmonic arteries in patients with acute hemoptysis, demonstrating that the risk of small shunts and displacement of the embolic agent is lower using Onyx™ compared using PVA particles. In addition, embolization with Onyx™ allows a longer time for proper placement of the embolic agent compared with glue embolization.

Study objective

To determine the technical and clinical success of BAE with the liquid embolic agent Onyx™ in patients with acute hemoptysis.

Materials and methods

Study Design

- This is a two-center retrospective study.
- Thirty-nine patients were identified who were admitted for BAE between March 2004 and April 2015; five of these patients (13%) were then excluded for various clinical reasons. In the remaining 34 patients (25 male, 9 female; mean age: 58y; age range, 13-78 years), BAE was performed with Onyx™.
- This study was approved by the institutional ethics committee of the institution and informed consent was obtained from each patient or a family member.
- Bronchoscopy was performed before the intervention. Contrast-enhanced computed tomography (CT) was performed to identify the feeding artery in all patients.

Patients' details	Value
Reasons for acute bleeding (%)	
• Bronchial carcinoma	44%
• Pulmonary metastasis of extra thoracic malignancies	12%
• Bronchiectasis	21%
• Arteriovenous malformation	6%
• Tuberculosis	6%
• Aspergilloma	3%
• Acute respiratory distress syndrome	3%
• Anticoagulation overdose	3%
• Scar tissue after shooting trauma	3%
Patients with right side of the lung affected (%)	65%
Patients with left side of the lung affected (%)	24%
Patients with both sides of the lung affected (%)	12%
Local anesthesia	61%
General anesthesia	40%

Embolization technique

BAE was performed through a 5-F femoral access in all cases.

The most likely bleeding artery was selectively catheterized with a cobra-shaped catheter (e.g., 5-FCobra; Cook, Bloomington, Indiana) or a catheter with a reverse curve (SOS Omni Flush; Angio Dynamics, Latham, New York). Subsequently, a dimethyl sulfoxide-compatible microcatheter (e.g., Echelon 10, Apollo10, or Rebar 18; Medtronic) was super-selectively inserted and placed proximal to the bleeding vessel. The microcatheter was then pre-flushed with DMSO and then embolization with Onyx™ was performed under fluoroscopy.

Technical success was defined as complete occlusion of the feeding bronchial artery.

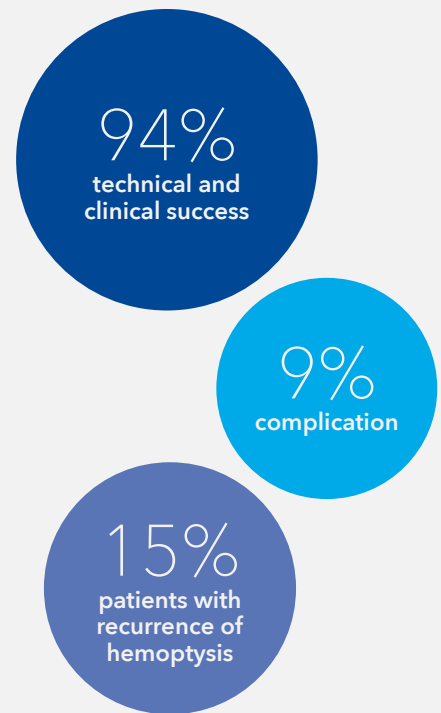Clinical success was defined as the absence of hemoptysis during 48 hours after the intervention.

Follow-up

In the present study, 24 patients (71%) underwent follow-up for a mean of 8.8 months (range, 5-1,150 d). Ten patients (29%) did not attend follow-up and had no further hospitalization.

Results

- 51 arteries embolized in 34 patients (range: 1-4 arteries per patient).
- Embolization was not completed in 2 patients as a result of unexpected early clumping of Onyx™ within the micro-catheter. As the bleeding stopped in both cases, interventions were considered clinically successful.
- Onyx™ used (mean): 2.5mL (range, 0.4-13.5 mL).
- Onyx™-18, Onyx™-20 and Onyx™-34 were used in 23 (68%), one (3%), and 10 (29%) patients, respectively.
- Additional material (coils, particles, microspheres, vascular plugs) was used to optimize results in 4 patients.
- 32/34 patients achieved hemostasis.
- During the follow-up, 5 patients (15%) experienced recurrence of hemoptysis:
 - 2 patients experienced relapse of hemoptysis at 2 weeks and 4 days after intervention, respectively
 - 2 patients experienced only a slight recurrence of hemoptysis, with no need of further intervention
 - In one patient, relapse of hemoptysis was detected during bronchoscopy and controlled without repeat intervention.
- One major and two minor complications (SIR classes B and D) occurred among the 34 patients (9%)



Conclusions

The use of Onyx™ for BAE in patients with acute hemoptysis is technically successful and safe and has a good clinical outcome with a low number of recurrences.

Medtronic

Europe
Medtronic International Trading Sàrl.
Route du Molliau 31
Case postale
CH-1131 Tolochenaz
www.medtronic.eu
Tel: +41 (0)21 802 70 00
Fax: +41 (0)21 802 79 00


See the device manual for detailed information regarding the instructions for use, indications, contraindications, warnings, precautions, and potential adverse events. For further information, contact your local Medtronic representative and/or consult the Medtronic website at medtronic.eu.

UC202300959EE © 2022 Medtronic.
All Rights Reserved.

medtronic.eu

Reference

Ayx I et al, "Treatment of Acute Hemoptysis by Bronchial Artery Embolization with the Liquid Embolic Agent Ethylene Vinyl Alcohol Copolymer". J Vasc Interv Radiol 2017; 28:825-831



Go to
article