

## “Endovascular Treatment of Pelvic Congestion Syndrome: Visual Analog Scale Follow-Up”

Sénéchal Q, et al. 2021



### Highlights:

1. Single center, retrospective study
2. 327 consecutive patients
3. Embolization with Onyx™
4. Follow-up 1, 6 and 12 months, then annually for 5 years
5. Pelvic pain significantly improved

### Background

- Pelvic Congestion Syndrome (PCS), which has recently been redefined as Pelvic Venous Disorders (PeVD), is one of the causes of Chronic Pelvic Pain (CPP).
- Transcatheter embolization therapy is a reference treatment among curative-intent options in the PCS/PeVD setting, but few published studies are available.
- The aim of embolization is to fill as many pelvic varicose veins as possible and to close venous communications and reflux veins.
- The Onyx™ Liquid Embolic System is an ethylene vinyl alcohol copolymer that allows easy fluoroscopic monitoring and control with less risk than coils and glue of additional migration or recanalization.

### Study objective

To evaluate the clinical mid-term outcome of transcatheter embolization (by using Onyx™) in women with PCS/PeVD. Pain relief and quality of life (QoL) were evaluated using a visual analog scale (VAS) scoring comparing before and after embolization.

### Materials and methods

#### Study design

- Single center, retrospective study involving consecutively recruited patients with PCS/PeVD or lower leg varices that underwent transcatheter embolization with Onyx™ from January 2014 to December 2019.
- 327 patients with CPP and/or lower limb varices were included in the study, of which:
  - 96% had Chronic Pelvic Pain
  - 72% had lower limb varices
  - 67% had a combination of both
  - 6.7% had Nutcracker syndrome
  - 4% had May-Thurner syndrome

Parameter	Cohort (n=327)
Age, mean (SD)	41.9 (11.6)
Endometriosis history, n (%)	73 (22.32%)
History of sclerotherapy, n (%)	85 (26%)
<b>Reason for embolization, n (%)</b>	
PCS/PeVD	312 (95.41%)
Leg varicose veins	15 (4.59%)

## Embolization technique

- All patients underwent embolization by using ethylene vinyl alcohol copolymer (Onyx™).
- 85 right ovarian veins, 249 left ovarian veins, 510 tributaries of the right internal iliac vein and 624 tributaries of the left internal iliac vein were embolized.
- 69 patients also underwent Nutcracker syndrome angioplasty (22) and May-Thurner syndrome angioplasty (47) with a stent placement.

## Follow-up

- Follow-up at 1, 6, and 12 months, and then annually for 5 years.
- Additional clinical data were collected for 288 patients via phone survey at mean 39 ±18-month post-surgery.

## Safety

16 minor and 4 major adverse events were reported during the follow-up.

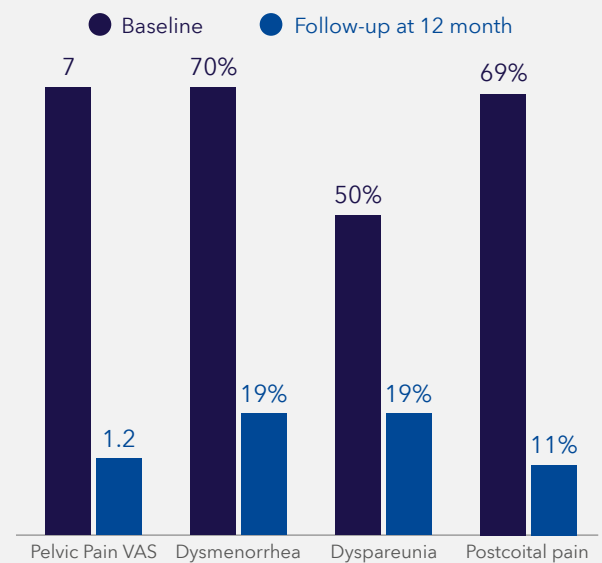
## Results

- Short-term success rate was 80.9% for embolization of pathological veins and 100% for stenting of stenoses.
- 14 patients (4.6%) required repeated treatment in an already embolized vein for recurrence of the symptoms.
- Improvement or disappearance of pain was achieved in 266/288 (92.36%) women.
- QoL improved in 276/288 (95.8%) patients.

**95.8%**  
patients achieved an improvement of QoL



**92.4%**  
patients achieved an improvement or disappearance of pain



## Conclusions

Embolization of pelvic veins with the Onyx™ Liquid Embolic System combined with stent placement has been shown to be an effective and safe technique, resulting in relevant clinical success with an overall improvement of pain and QoL for more than 90% of patients.

## Medtronic

Europe  
Medtronic International Trading Sàrl.  
Route du Molliau 31  
Case postale  
CH-1131 Tolochenaz  
www.medtronic.eu  
Tel: +41 (0)21 802 70 00  
Fax: +41 (0)21 802 79 00

See the device manual for detailed information regarding the instructions for use, indications, contraindications, warnings, precautions, and potential adverse events. For further information, contact your local Medtronic representative and/or consult the Medtronic website at medtronic.eu.

UC202216303EE © Medtronic 2022.  
All rights reserved.

medtronic.eu

### Reference

Sénéchal Q, et al. "Endovascular Treatment of Pelvic Congestion Syndrome: Visual Analog Scale Follow-Up". *Front. Cardiovasc. Med.* 2021 ; 8 :751178.



Go to article