

ACUSON Sequoia  
ACUSON Sequoia Select  
Diagnostic Ultrasound System  
Instructions for Use



An updated User and Reference Manual may be available for your ultrasound system. Access the most recent manual from the Siemens Healthineers Document Library at [doclib.siemens-healthineers.com](https://doclib.siemens-healthineers.com)

---

**ACUSON Sequoia**

Product Version 3.5

Software Version VB30

**ACUSON Sequoia Select**

Product Version 3.0

Software Version VB30

©2018-2024 Siemens Medical Solutions USA, Inc.

All Rights Reserved.

Date of first issue: 2024-11

All trademarks are property of their respective owners. The following trademarks of Siemens Healthineers AG or its affiliates are registered or pending with the U.S. Patent and Trademark Office:

ACUSON, ACUSON Sequoia, Sequoia, *syngo*, TEQ, Virtual Touch

The user documentation includes references to third-party products for informational purposes only. These references do not represent an endorsement of the third-party products referenced in the user documentation or an assumption of responsibility for the performance of third-party products.

Siemens Medical Solutions USA, Inc. reserves the right to change its products and services at any time. In addition, this publication is subject to change without notice.

**Manufacturer**

Siemens Medical Solutions USA, Inc.  
Ultrasound  
22010 S.E. 51st Street  
Issaquah, WA 98029  
U.S.A.  
Phone: +1-888-826-9702  
[siemens-healthineers.com](https://siemens-healthineers.com)

**Siemens Healthineers Headquarters**

Siemens Healthineers AG  
Siemensstr. 3  
91301 Forchheim  
Germany  
Phone: +49 9191 18-0  
[siemens-healthineers.com](https://siemens-healthineers.com)

# Contents

---

- Chapter 1 Introduction**  
Overview of the diagnostic ultrasound imaging system, intended use, and a detailed description of the touch screen and control panel.
- Chapter 2 Safety and Care**  
Detailed information on the safety and care of the ultrasound system. Includes information on system maintenance.
- Chapter 3 Transducer Care and Accessories**  
Detailed information on caring for transducers. Includes procedures for cleaning and disinfecting transducers. Also includes information on compatible transducer accessories.
- Chapter 4 System Setup**  
Detailed descriptions for setting up and preparing the system for use. Includes information for transporting the system.
- Chapter 5 Beginning a Study**  
Procedures for preventing unauthorized access to the ultrasound system; registering a patient; selecting a transducer, exam association, and operating mode; and capturing an image or clip.
- Chapter 6 Workflow Protocols**  
Procedures for activating and editing a protocol to guide you through a predefined clinical workflow.
- Chapter 7 CINE**  
Procedures for playing back data in the CINE memory buffer.
- Chapter 8 Image Optimization**  
Procedures for optimizing parameters for each basic operating mode. Includes procedures for creating and editing user-defined image presets.
- Chapter 9 Annotations**  
Procedures for annotating with text, directional arrows, and body markers.

<b>Chapter 10</b>	<b>Measurements and Calculations</b> Description of the measurement function with procedures for using basic measurement tools for 2D-mode, Doppler, and M-mode. Includes the following features or measurement and calculation packages: <ul style="list-style-type: none"><li>▪ Obstetric</li></ul>
<b>Chapter 11</b>	<b>Cardiac Measurements and Calculations</b> Description of the measurement function with procedures for using measurement tools specific to the cardiac imaging use cases. Includes the following features or measurement and calculation packages: <ul style="list-style-type: none"><li>▪ 3D Caliper</li><li>▪ AI Measure</li></ul>
<b>Chapter 12</b>	<b>Reports</b> Procedures for saving, modifying, and transferring reports.
<b>Chapter 13</b>	<b>Printing and Recording</b> Procedures for printing and recording images.
<b>Appendix A</b>	<b>Technical Description</b> Technical description of the ultrasound system. Includes the operating and storage temperatures for the system and transducers.
<b>Appendix B</b>	<b>Icons and Indicators</b> Description of system status indicators, special characters, and the imaging parameters and settings on the image screen.
<b>Appendix C</b>	<b>Cybersecurity</b> Information about ultrasound system security.
<b>Appendix D</b>	<b>Acoustic Output Reference</b> Acoustic output reporting tables.

**Note:** Not all features and options described in this publication are available to all users. Please check with your Siemens Healthineers representative to determine the current availability of features and options.

## About the User and Reference Manuals



The user and reference manuals consist of the following publications.

Publication	Includes
<i>Instructions for Use</i>	<ul style="list-style-type: none"><li>▪ Conventions and typographical conventions used in the manuals</li><li>▪ Intended audience</li><li>▪ Introduction to the ultrasound system</li><li>▪ Safety and care information for the ultrasound system and compatible transducers</li><li>▪ Procedures for setting up and preparing the system for use</li><li>▪ Procedures for registering a patient and activating an operating mode</li><li>▪ Procedures for acquiring, optimizing, annotating, measuring, printing, and recording images</li><li>▪ Technical description of the ultrasound system</li><li>▪ Acoustic output data</li></ul>
<i>Advanced Imaging Manual</i>	<p>This manual is a companion to the Instructions for Use publication and contains additional instructions for use for the safe and proper use of advanced imaging features on the ultrasound system.</p> <ul style="list-style-type: none"><li>▪ Description of the biopsy function</li><li>▪ Procedures for specialty imaging<ul style="list-style-type: none"><li>– Panoramic imaging</li><li>– Contrast agent imaging</li><li>– Comparing images from multiple modalities</li><li>– AI anatomy recognition, including AI Assist and AI Abdomen</li><li>– 3D and 4D volume imaging</li><li>– Virtual Touch applications</li><li>– Fusion imaging</li></ul></li><li>▪ Procedures for reviewing images and clips</li><li>▪ Description of features for cardiology<ul style="list-style-type: none"><li>– Procedures for the physiologic function</li><li>– Procedures for the stress echo function</li><li>– Description of the transesophageal transducer, including cleaning and care of the transducer</li><li>– Cardiac volume imaging<ul style="list-style-type: none"><li>– 2D Heart AI</li><li>– 4D Heart AI</li></ul></li></ul></li></ul>
<i>System Reference*</i>	<ul style="list-style-type: none"><li>▪ Description of customizable system settings</li><li>▪ Description of all measurement labels configurable for the ultrasound system</li><li>▪ Information about DICOM connectivity, network capabilities, and external devices</li><li>▪ Clinical references</li><li>▪ Information regarding the electromagnetic compatibility (EMC) testing of this ultrasound system</li></ul>

\*Languages supported by the user interface include a translation of this publication.

## Conventions

The user and reference manuals include the following conventions.

Convention	Description
Warnings and Cautions	<p> <b>WARNING:</b> Warnings are intended to alert you to the importance of following the correct operating procedures where risk of injury to the patient or system user exists.</p> <p> <b>Caution:</b> Cautions are intended to alert you to the importance of following the correct operating procedures to prevent the risk of damage to the ultrasound system.</p>
Notes and Prerequisites	<p><b>Prerequisite:</b> Prerequisites contain tasks the user must complete or information the user needs prior to performing a procedure.</p> <p><b>Note:</b> Notes contain information concerning the proper use of the ultrasound system or correct execution of a procedure.</p>
Cross-references	<p>Examples:</p> <p><b>See also:</b> For information about cleaning and disinfecting a transducer, refer to Chapter 3 in this manual.</p> <p><b>See also:</b> For information about customizing the measurement function, refer to Chapter 2 in the System Reference.</p> <p><b>See also:</b> For additional information about the measurement function, refer to Chapter 10 in the Instructions for Use.</p> <p><b>See also:</b> For information about exporting and importing images, refer to Chapter B2 in the Advanced Imaging Manual.</p> <p><b>See also:</b> Alphanumeric Keyboard, page 1-26</p> <p><b>See also:</b> Chapter 2, Instructions for Use</p>
Customizable Ultrasound System Settings	<p>Settings for configuring and customizing the ultrasound system are described in the System Reference. When customization is available, the user manual provides a reference to the configuration settings.</p> <p>Example:</p> <p>Use the configuration settings to customize the measurement function.</p>

## Typographical Conventions

The following typographical conventions are in descriptions and procedures within your user and reference manuals. Use the conventions to identify the location of a control or selection on the ultrasound system.

Control or Selection	Description
Controls on the Control Panel	Controls located on the control panel are indicated by uppercase boldface type. Examples: <ul style="list-style-type: none"><li>▪ Rotate <b>2D</b> to adjust the 2D gain.</li><li>▪ Press <b>ABC</b> to activate or exit the annotation function.</li><li>▪ Double-click <b>UPDATE</b> to display the 2D image.</li></ul>
Trackball and Trackball Keys	Right and left trackball keys are located on the control panel. The function assigned to the trackball and trackball keys is indicated by labels on the image screen. Examples: <ul style="list-style-type: none"><li>▪ Adjust the size or position of the field of view and then press a trackball key.</li><li>▪ Position the measurement marker and then press a trackball key.</li><li>▪ Press the right trackball key.</li></ul>
Selections on the Image Screen	On-screen selections are indicated by boldface type. Roll the trackball to position the pointer on the control or object on the image screen and then press a trackball key. Examples: <ul style="list-style-type: none"><li>▪ Click <b>Correct</b> on the patient registration form.</li><li>▪ Double-click a thumbnail.</li><li>▪ Select the check box for the required entries and then click <b>Delete</b>.</li></ul>
Controls on the Control Panel for the Touch Screen	Press and rotate controls on the control panel are labeled on the touch screen. The selection assigned to these controls is indicated by boldface type. Examples: <ul style="list-style-type: none"><li>▪ Rotate <b>Tint</b>.</li><li>▪ Press <b>Steer</b>.</li></ul>
Selections on the Touch Screen	Touch screen selections are indicated by boldface type. Tap the touch screen to access a selection. Drag an object on the touch screen to reposition the object. Swipe the screen to display a separate page of selections. Examples: <ul style="list-style-type: none"><li>▪ Tap <b>Workflow</b>.</li><li>▪ Drag the tail of the arrow on the touch screen to adjust the length.</li></ul>



# 1 Introduction

---

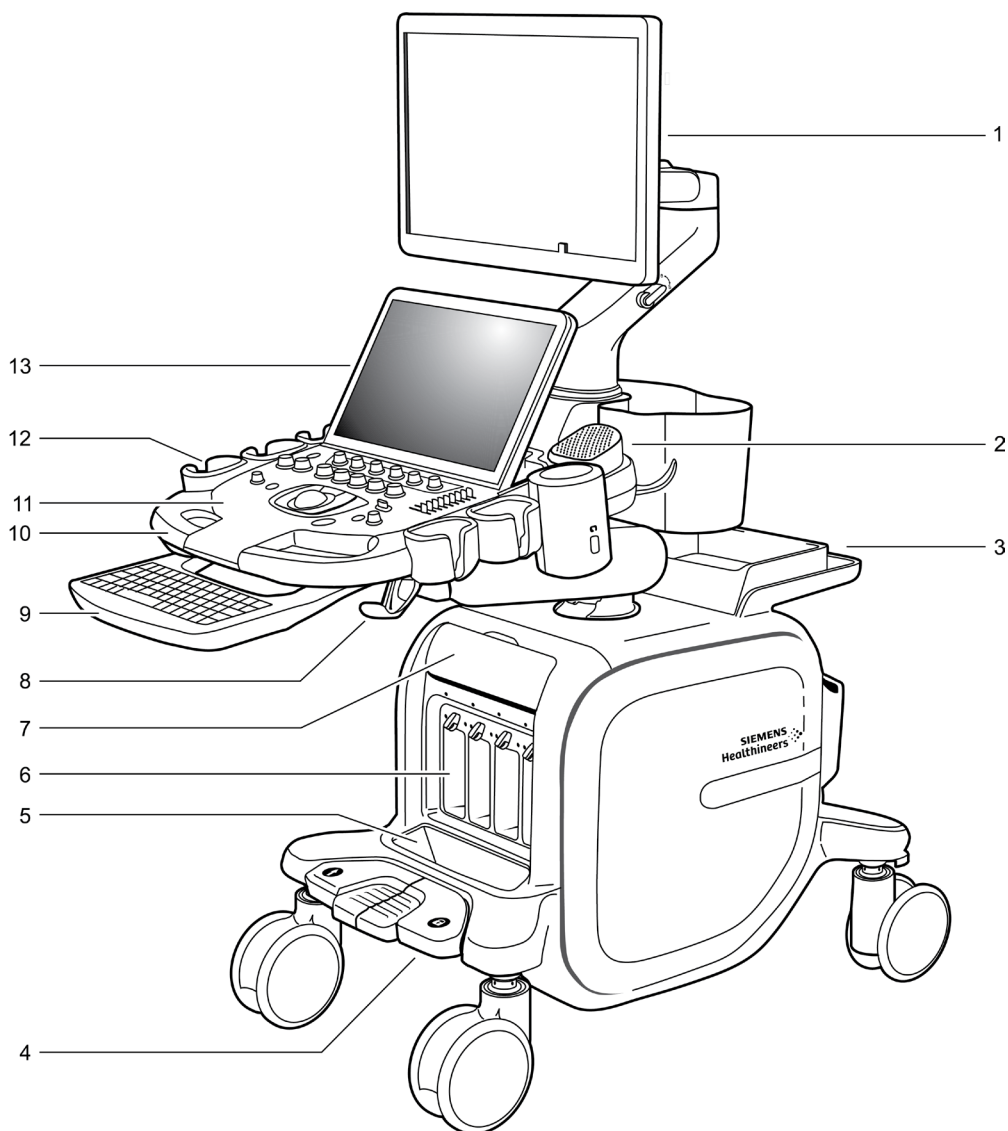
<b>System Overview</b> .....	<b>3</b>
<b>Intended Use</b> .....	<b>6</b>
Indications for Use Statement.....	6
Operating Modes.....	7
Patient Target Groups.....	7
Intended Use Environment.....	7
Intended Users.....	8
Contraindications.....	8
Transducers and Intended Applications .....	9
<b>Principles of Operation</b> .....	<b>13</b>
<b>Clinical Benefits</b> .....	<b>13</b>
<b>Image Screen Overview</b> .....	<b>14</b>
Cursor Function and Depth Indicators .....	16
Screen Saver.....	16
<b>Touch Screen Overview</b> .....	<b>17</b>
Main Navigation Selections on the Touch Screen .....	19
Additional Selections and Symbols on the Touch Screen .....	19
<b>Control Panel with Orange Backlighting</b> .....	<b>21</b>
Annotation, Measurement, and Archive Controls .....	22
Trackball and Trackball Keys.....	23
Trackball Status Indicator.....	23
Operating Mode Controls.....	24
Image Format Controls.....	25
<b>Control Panel with Blue Backlighting</b> .....	<b>26</b>
Annotation, Measurement, and Archive Controls .....	27
Trackball and Trackball Keys.....	28
Trackball Status Indicator.....	28
Operating Mode Controls.....	29
Image Format Controls.....	31
<b>Footswitch</b> .....	<b>32</b>
<b>Retractable Keyboard</b> .....	<b>32</b>
Special Keys on the Retractable Keyboard .....	32
<b>Configuring the Ultrasound System</b> .....	<b>32</b>



## System Overview

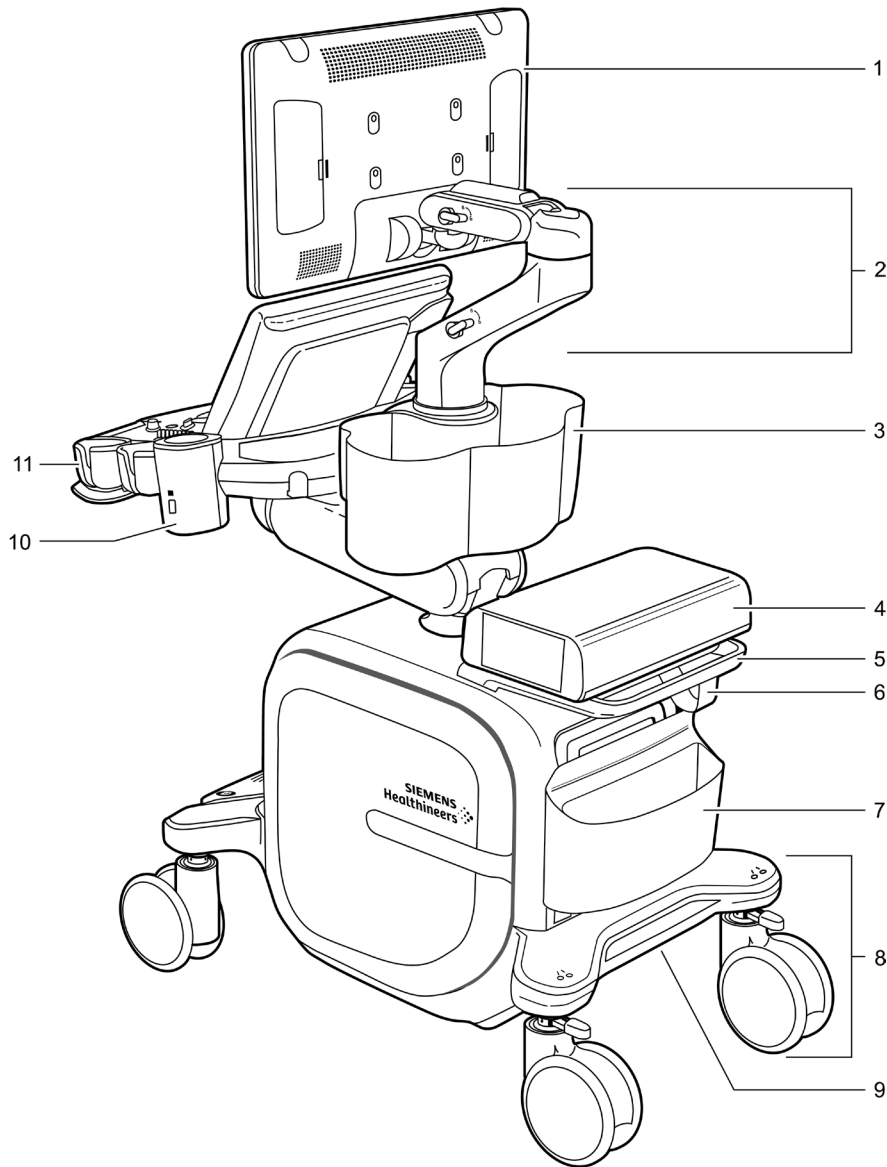
The ACUSON Sequoia and ACUSON Sequoia Select ultrasound systems are designed for diagnostic use in general imaging, vascular, and cardiac imaging. The systems streamline clinical workflow from patient registration to study archival with software-based applications, transducers, and clinical communication tools.

**See also:** For a technical description of the ultrasound systems, refer to Appendix A in this manual.



*Example of the ultrasound system, front view.*

- 1 Monitor
- 2 Speaker
- 3 Accessory shelf. This example includes the optional printer.  
Accommodates an optional accessory, for example, a printer, recordable disc drive, Fusion electronics unit, or rear accessory tray
- 4 Lock and swivel lock for the front wheels
- 5 Storage bin for transducer connectors
- 6 Transducer ports for array transducers
- 7 Access door for ports
  - Auxiliary continuous wave Doppler transducer port
  - Auxiliary in/out port for the physiologic function
  - ECG port
- 8 Transducer cable hook
- 9 Keyboard (optional)
- 10 Front handle
- 11 Backlit control panel
- 12 Transducer holder
- 13 Touch screen with USB ports



*Example of the ultrasound system, back view.*

- 1 Monitor
- 2 Adjustable arm for the monitor
- 3 Storage bin
- 4 Accessory shelf. This example includes the optional printer.  
Accommodates an optional accessory, for example, a printer, recordable disc drive, Fusion electronics unit, or rear accessory tray
- 5 Rear handle for repositioning the ultrasound system  
This handle is not intended for moving the system to another location.
- 6 Power cord hook
- 7 Storage bin and access door for connections and indicators
  - Input/output panel
  - Ethernet port
  - Service indicator lights
- 8 Rear swivel wheel with locking lever
- 9 Power panel
- 10 Gel warmer
- 11 Transducer holder

## Selecting an Exam Association Package

An exam association package includes an image preset, a measurement and report calculation package, annotation body markers, annotation text package, and protocol. You can select measurement labels, text annotations, body markers, or protocols without changing the image preset or exam association package.

### To select an exam association package:

**Prerequisite:** Activate the measurement function or the annotation function.

1. Tap **Exam Package**.
2. Tap the required selection:

<b>Selection</b>	<b>Description</b>
<b>Abdomen</b>	Abdomen
<b>Breast</b>	Breast
<b>Cardiac</b>	Cardiac
<b>Carotid</b>	Cerebrovascular
<b>Early OB</b>	Early obstetric
<b>Fetal Echo</b>	Fetal echo
<b>GYN</b>	Gynecological
<b>LEA</b>	Peripheral vascular arterial, lower extremity
<b>LEV</b>	Peripheral vascular venous, lower extremity
<b>MSK</b>	Musculoskeletal
<b>Neo Head</b>	Neonatal head
<b>Neonatal Head</b>	Neonatal head
<b>OB</b>	Obstetric
<b>Ped Hip</b>	Pediatric hip
<b>Pediatric Abdomen</b>	Pediatric abdomen
<b>Pelvis</b>	Pelvis
<b>Penile</b>	Penile
<b>Prostate</b>	Prostate
<b>Renal</b>	Renal
<b>TCI</b>	Transcranial imaging
<b>Testis</b>	Testis
<b>Thyroid</b>	Thyroid
<b>UEA</b>	Peripheral vascular arterial, upper extremity
<b>UEV</b>	Peripheral vascular venous, upper extremity

## Optimizing 2D Images

**Prerequisite:** Activate 2D imaging. During combined mode imaging, tap the **2D** tab to access the optimization settings.

To	Do This
Resize or reposition the field of view (FOV)	<p>(Available only for phased and curved array transducers with curved and vector formats)</p> <ol style="list-style-type: none"> <li>Press a trackball key, if necessary. <ul style="list-style-type: none"> <li><b>Position</b> indicates the trackball is assigned to repositioning the FOV. A dashed line outlines the FOV.</li> <li><b>Size</b> indicates the trackball is assigned to adjusting the width of the FOV. A dotted line outlines the FOV.</li> <li><b>Set</b> indicates the trackball is no longer assigned to adjusting the FOV. The system removes the outline from the FOV.</li> </ul> </li> <li>Roll the trackball to adjust the size or position and then press a trackball key.</li> </ol>
Restore the field of view (FOV) to the default position and maximum size	<p>(Available only for vector and curved transducers, and linear array transducers in a trapezoid image format)</p> <p>(Not available during Doppler and M-mode imaging)</p> <ul style="list-style-type: none"> <li>Tap <b>Full FOV</b>.</li> </ul>
Expand the width of the acquisition field of view (FOV)	<p>(Not available during Zoom or HD Zoom)</p> <ul style="list-style-type: none"> <li>Tap <b>Wide FOV</b>.</li> <li>To exit, tap <b>Wide FOV</b> again.</li> </ul>
Reduce or enlarge the size of the 2D image	<ul style="list-style-type: none"> <li>Tap <b>Image Size</b> and then select a size setting.</li> </ul>
Rotate an image	<p>(Available only for linear array transducers)</p> <p>(Not available during seamless dual imaging)</p> <ul style="list-style-type: none"> <li>To rotate the image 90 degrees in a clockwise direction, tap <b>90°</b>.</li> <li>To rotate the image 90 degrees in a counterclockwise direction, tap <b>270°</b>.</li> <li>To reset to the starting position, tap <b>0°</b>.</li> </ul> <p><b>Note:</b> Only the active image rotates during dual imaging. Both images rotate during live dual imaging.</p>
Activate a linear or trapezoid image format	<p>(Available only for linear array transducers)</p> <ul style="list-style-type: none"> <li>Tap <b>Trapezoid</b>.</li> </ul>

## M-mode Measurements

### M-mode Measurement Labels

Measurement Label	Definition
<b>M-mode</b>	M-mode
<b>Ao/LA</b>	Aorta/left atrium measurements
<b>Ao Diam d</b>	Aortic diameter at end-diastole
<b>AoV Cusp Sep</b>	Aortic valve cusp separation
<b>LA Diam s</b>	Left atrial diameter systole
<b>IVC</b>	Inferior vena cava
<b>IVC Collapsed Diam</b>	Inferior vena cava collapsed diameter
<b>IVC Diam</b>	Inferior vena cava diameter
<b>MV</b>	Mitral valve function
<b>CE Amp</b>	Amplitude of the E wave
<b>CA Amp</b>	Amplitude of the A wave
<b>DE Excursion</b>	DE excursion
<b>DE Slope</b>	Anterior excursion of the mitral leaflet at early diastole
<b>EPSS</b>	E point to septal separation The distance between the anterior leaflet and the ventricular septum at early diastole.
<b>EF Slope</b>	Deceleration slope of the mitral leaflet's closure at early diastole
<b>MAPSE</b>	Mitral valve annular plane systemic excursion
<b>Systolic BP</b>	Systolic blood pressure
<b>TV</b>	Tricuspid valve
<b>DE Excursion</b>	DE excursion
<b>DE Slope</b>	Anterior excursion of the mitral leaflet at early diastole
<b>EF Slope</b>	Deceleration slope of the mitral leaflet's closure at early diastole
<b>TAPSE</b>	Tricuspid annular plane systolic excursion
<b>RV</b>	Right ventricle dimensions
<b>RV ET</b>	Right ventricular ejection time
<b>RV Inflow Vp</b>	Right ventricular inflow propagation velocity
<b>RV PEP</b>	Right ventricular pre-ejection period
<b>RVAW d</b>	Right ventricular anterior wall at end-diastole
<b>RVAW s</b>	Right ventricular anterior wall at end-systole
<b>RVID d</b>	Right ventricular internal diameter at end-diastole
<b>RVID s</b>	Right ventricular internal diameter at end-systole

## 2D Heart AI Result Labels

**See also:** For information about the 2D Heart AI feature, refer to Chapter D3 in the Advanced Imaging Manual.

### 2D Heart AI General Labels

Result Label	Description	Units
HR	Heart rate	bpm

### 2D Heart AI Left Ventricle Pre-tracking Measurement Labels

Result Label	Description	Units
<b>A4C Pre-tracking</b>	Apical four chamber pre-tracking	---
<b>EF</b>	Ejection fraction	%
<b>GLS</b>	Global longitudinal strain	%
<b>Mass</b>	Mass	g
<b>Mass/BSA</b>	Mass, body surface area	g/m <sup>2</sup>
<b>CO</b>	Cardiac output	l/min
<b>EDV</b>	End diastolic volume	ml
<b>EDV/BSA</b>	End diastolic volume, body surface area	ml/m <sup>2</sup>
<b>ESV</b>	End systolic volume	ml
<b>ESV/BSA</b>	End systolic volume, body surface area	ml/m <sup>2</sup>
<b>SV</b>	Stroke volume	ml
<b>SV/BSA</b>	Stroke volume, body surface area	ml/m <sup>2</sup>
<b>ED Axis</b>	End diastolic major axis	cm
<b>ES Axis</b>	End systolic major axis	cm
<b>A2C Pre-tracking</b>	Apical two chamber pre-tracking	---
<b>EF</b>	Ejection fraction	%
<b>GLS</b>	Global longitudinal strain	%
<b>Mass</b>	Mass	g
<b>Mass/BSA</b>	Mass, body surface area	g/m <sup>2</sup>
<b>CO</b>	Cardiac output	l/min
<b>EDV</b>	End diastolic volume	ml
<b>EDV/BSA</b>	End diastolic volume, body surface area	ml/m <sup>2</sup>
<b>ESV</b>	End systolic volume	ml
<b>ESV/BSA</b>	End systolic volume, body surface area	ml/m <sup>2</sup>
<b>SV</b>	Stroke volume	ml
<b>SV/BSA</b>	Stroke volume, body surface area	ml/m <sup>2</sup>
<b>ED Axis</b>	End diastolic major axis	cm
<b>ES Axis</b>	End systolic major axis	cm

Result Label	Description	Units
<b>A3C Pre-tracking</b>	Apical three chamber pre-tracking	---
<b>EF</b>	Ejection fraction	%
<b>GLS</b>	Global longitudinal strain	%
<b>CO</b>	Cardiac output	l/min
<b>EDV</b>	End diastolic volume	ml
<b>EDV/BSA</b>	End diastolic volume, body surface area	ml/m <sup>2</sup>
<b>ESV</b>	End systolic volume	ml
<b>ESV/BSA</b>	End systolic volume, body surface area	ml/m <sup>2</sup>
<b>SV</b>	Stroke volume	ml
<b>SV/BSA</b>	Stroke volume, body surface area	ml/m <sup>2</sup>
<b>ED Axis</b>	End diastolic major axis	cm
<b>ES Axis</b>	End systolic major axis	cm

## 2D Heart AI Left Atrium Pre-tracking Measurement Labels

Result Label	Description	Units
<b>A4C Pre-tracking</b>	Apical four chamber pre-tracking	---
<b>EF</b>	Ejection fraction	%
<b>EDA</b>	End diastolic area	cm <sup>2</sup>
<b>ESA</b>	End systolic area	cm <sup>2</sup>
<b>FAC</b>	Fractional area change	%
<b>GLS</b>	Global longitudinal strain	%
<b>CO</b>	Cardiac output	l/min
<b>EDV</b>	End diastolic volume	ml
<b>EDV/BSA</b>	End diastolic volume, body surface area	ml/m <sup>2</sup>
<b>ESV</b>	End systolic volume	ml
<b>ESV/BSA</b>	End systolic volume, body surface area	ml/m <sup>2</sup>
<b>SV</b>	Stroke volume	ml
<b>SV/BSA</b>	Stroke volume, body surface area	ml/m <sup>2</sup>
<b>ED Axis</b>	End diastolic major axis	cm
<b>ES Axis</b>	End systolic major axis	cm
<b>A2C Pre-tracking</b>	Apical two chamber pre-tracking	---
<b>EF</b>	Ejection fraction	%
<b>GLS</b>	Global longitudinal strain	%
<b>CO</b>	Cardiac output	l/min
<b>EDV</b>	End diastolic volume	ml
<b>EDV/BSA</b>	End diastolic volume, body surface area	ml/m <sup>2</sup>
<b>ESV</b>	End systolic volume	ml
<b>ESV/BSA</b>	End systolic volume, body surface area	ml/m <sup>2</sup>
<b>SV</b>	Stroke volume	ml
<b>SV/BSA</b>	Stroke volume, body surface area	ml/m <sup>2</sup>
<b>ED Axis</b>	End diastolic major axis	cm
<b>ES Axis</b>	End systolic major axis	cm

**2D Heart AI Left Atrium Pre-tracking Measurement Labels**

<b>Result Label</b>	<b>Description</b>	<b>Units</b>
<b>Right Ventricle A4C Pre-tracking</b>	Right ventricle apical four chamber pre-tracking	---
<b>EF</b>	Ejection fraction	%
<b>GLS</b>	Global longitudinal strain	%
<b>CO</b>	Cardiac output	l/min
<b>EDV</b>	End diastolic volume	ml
<b>EDV/BSA</b>	End diastolic volume, body surface area	ml/m <sup>2</sup>
<b>ESV</b>	End systolic volume	ml
<b>ESV/BSA</b>	End systolic volume, body surface area	ml/m <sup>2</sup>
<b>SV</b>	Stroke volume	ml
<b>SV/BSA</b>	Stroke volume, body surface area	ml/m <sup>2</sup>
<b>ED Axis</b>	End diastolic major axis	cm
<b>ES Axis</b>	End systolic major axis	cm

**2D Heart AI Biplane Measurement Labels**

<b>Result Label</b>	<b>Description</b>	<b>Units</b>
<b>Left Ventricle Biplane</b>	Left ventricle biplane	---
<b>EF</b>	Ejection fraction	%
<b>GLS</b>	Global longitudinal strain	%
<b>Mass</b>	Mass	g
<b>Mass/BSA</b>	Mass, body surface area	g/m <sup>2</sup>
<b>CO</b>	Cardiac output	l/min
<b>EDV</b>	End diastolic volume	ml
<b>EDV/BSA</b>	End diastolic volume, body surface area	ml/m <sup>2</sup>
<b>ESV</b>	End systolic volume	ml
<b>ESV/BSA</b>	End systolic volume, body surface area	ml/m <sup>2</sup>
<b>SV</b>	Stroke volume	ml
<b>SV/BSA</b>	Stroke volume, body surface area	ml/m <sup>2</sup>
<b>ED Axis</b>	End diastolic major axis	cm
<b>ES Axis</b>	End systolic major axis	cm

<b>Result Label</b>	<b>Description</b>	<b>Units</b>
<b>Left Atrium Biplane</b>	Left atrium biplane	---
<b>EF</b>	Ejection fraction	%
<b>GLS</b>	Global longitudinal strain	%
<b>CO</b>	Cardiac output	l/min
<b>EDV</b>	End diastolic volume	ml
<b>EDV/BSA</b>	End diastolic volume, body surface area	ml/m <sup>2</sup>
<b>ESV</b>	End systolic volume	ml
<b>ESV/BSA</b>	End systolic volume, body surface area	ml/m <sup>2</sup>
<b>SV</b>	Stroke volume	ml
<b>SV/BSA</b>	Stroke volume, body surface area	ml/m <sup>2</sup>
<b>ED Axis</b>	End diastolic major axis	cm
<b>ES Axis</b>	End systolic major axis	cm
<b>Overall Global Longitudinal Strain</b>	Overall global longitudinal strain	---
<b>Overall GLS</b>	Overall global longitudinal strain	%

## 2D Heart AI Tracking Results Summary

<b>Result Label</b>	<b>Description</b>	<b>Units</b>
<b>Left Ventricle Summary</b>	Left ventricle summary	---
<b>AVG EF</b>	Averaged ejection fraction	%
<b>PSD</b>	Peak strain dispersion (systolic)	ms
<b>AVC</b>	Aortic valve closure	ms
<b>Left Atrium Summary</b>	Left atrium summary	---
<b>AVG GLS Cond</b>	Averaged global longitudinal strain, conduit	%
<b>AVG GLS Cont</b>	Averaged global longitudinal strain, contraction	%
<b>AVG GLS Res</b>	Averaged global longitudinal strain, reservoir	%
<b>AVG ESV</b>	Averaged end systolic volume	ml
<b>AVG ESV/BSA</b>	Averaged end systolic volume, body surface area	ml/m <sup>2</sup>
<b>Pre-A</b>	Pre-atrial contraction time measured at the onset of the P-wave	ms

**2D Heart AI Single View Tracking Results Labels**

<b>Result Label</b>	<b>Description</b>	<b>Units</b>
<b>Left Atrium A4C Tracking</b>	Left atrium apical four chamber tracking	---
<b>GLS Cond</b>	Global longitudinal strain, conduit	%
<b>GLS Cont</b>	Global longitudinal strain, contraction	%
<b>GLS Res</b>	Global longitudinal strain, reservoir	%
<b>Left Atrium A2C Tracking</b>	Left atrium apical two chamber tracking	---
<b>GLS Cond</b>	Global longitudinal strain, conduit	%
<b>GLS Cont</b>	Global longitudinal strain, contraction	%
<b>GLS Res</b>	Global longitudinal strain, reservoir	%

**2D Heart AI Bullseye Result Labels**

<b>Result Label</b>	<b>Description</b>	<b>Units</b>
<b>ESS</b>	Left ventricle end systolic strain	%
<b>PS</b>	Left ventricle post systolic strain	%
<b>PSI</b>	Left ventricle post systolic indexed	---
<b>PSS</b>	Left ventricle peak systolic strain	%
<b>TTP</b>	Left ventricle time to peak	ms

**2D-mode Obstetric Fetal Echo Measurement Labels**

Measurement Label	Definition
AC	Abdominal circumference
AFI - Q1	Amniotic fluid index for the quadrant, numbered 1 through 4
APTD	Anterior posterior trunk diameter
BPD	Biparietal diameter
Cardiac Axis	Cardiac axis
Cerebellum	Cerebellum
FL	Femur length
HA	Heart area
HC	Head circumference
Heart Circum	Heart circumference
HL	Humerus length
HW	Hemispheric width
Lat Vent	Lateral ventricle
OFD	Occipital frontal diameter
TA	Thoracic area
TC	Thoracic circumference
TTD	Transverse thoracic diameter

**Doppler Obstetric Fetal Echo Measurement Labels**

Measurement Label	Definition
MCA	Middle cerebral artery
Umbilical A	Umbilical artery
Umbilical V A Vmax	Umbilical vein A wave, maximum velocity
Umbilical V D Vmax	Umbilical vein D wave, maximum velocity
Umbilical V S Vmax	Umbilical vein S wave, maximum velocity
Umbilical V VT1	Umbilical vein, velocity time integral
Uterine A	Uterine artery

**M-mode Fetal Echo Measurement Labels**

Measurement Label	Definition
LVID	Left ventricular internal diameter
MAPSE	Mitral annular plane systolic excursion
PR Interval	Time interval P-R
RVFW	Right valve free wall
RVID	Right ventricular internal diameter
TAPSE	Tricuspid annular plane systolic excursion
LV d Series	Left ventricle diastolic measurement series
LV s Series	Left ventricle systolic measurement series

## Appendix F Bibliography

---

<b>Cardiac Clinical References</b> .....	<b>3</b>
Adult Cardiac .....	3
Pediatric Cardiac .....	7
2D Heart AI and 4D Heart AI .....	8
<b>Fetal Echo Clinical References</b> .....	<b>9</b>
Fractional Shortening .....	9
Cardiothoracic Ratio .....	9
Mean Pressure Gradient.....	9
Mitral Valve Peak E Wave Velocity to Peak A Wave Velocity Ratio .....	9
Peak Pressure Gradient .....	9
Tei Index (Myocardial Performance Index).....	9
Z-Score Calculations .....	9
<b>Obstetric Clinical References</b> .....	<b>10</b>
Simple Gestational Age Calculations.....	10
Composite Gestational Age Calculations.....	15
Estimated Fetal Weight Calculations .....	16
Ratio Calculations.....	18
Growth Analysis Calculations .....	19
Additional Obstetric References .....	27
<b>Pediatric Hip Clinical References</b> .....	<b>28</b>
<b>Transcranial Imaging Clinical References</b> .....	<b>28</b>
<b>Ultrasound-Derived Fat Fraction Clinical References</b> .....	<b>28</b>
<b>Stress Echo Clinical References</b> .....	<b>29</b>
<b>Pulsatility Index Calculation References</b> .....	<b>29</b>
<b>Virtual Touch Clinical References</b> .....	<b>29</b>
<b>Vascular Clinical References</b> .....	<b>29</b>
Carotid Intima-Media Thickness .....	29
<b>Volume Clinical References</b> .....	<b>30</b>
Thyroid.....	30



## Cardiac Clinical References

- Chambless LE, Heiss G, Folsom AR, Rosamond W, Szklo M, Sharrett AR, Clegg LX. "Association of Coronary Heart Disease Incidence with Carotid Arterial Wall Thickness and Major Risk Factors: The Atherosclerosis Risk in Communities (ARIC) Study, 1987–1993." *American Journal of Epidemiology* 146(6):483–494, 1997.
- Howard G, Sharrett A, Heiss G, Evans G, Chambless L, Riley W, Burke GL. "Carotid Artery Intimal-medial Thickness Distribution in General Populations as Evaluated by B-mode Ultrasound." *Stroke* 24(9):1297–1304, 1993.
- Schiller NB, Shah PM, Crawford M, DeMaria A, Devereux R, et al. "Recommendations for Quantification of the Left Ventricle by Two-dimensional Echocardiography." *Journal of the American Society of Echocardiography* 2(5):358–367, 1989.
- Stein JH, Fraizer MC, Aeschlimann SE, Nelson-Worel J, McBride PE, Douglas PS. "Vascular Age: Integrating Carotid Intima-media Thickness Measurements with Global Coronary Risk Assessment." *Clinical Cardiology* 27(7):388–392, 2004.
- Stein JH, Korcarz CE, Hurst RT, Lonn E, Kendall CB, Mohler ER, Najjar SS, Rembold CM, Post WS. "Use of Carotid Ultrasound to Identify Subclinical Vascular Disease and Evaluate Cardiovascular Disease Risk: A Consensus Statement from the American Society of Echocardiography Carotid Intima-Media Thickness Task Force." *Journal of the American Society of Echocardiography* 21(2):93–111, 2008.
- Stein JH, Korcarz CE, Mays ME, Douglas PS, Palta M, Zhang H, LeCaire T, Paine D, Gustafson D, Fan L. "A Semiautomated Ultrasound Border Detection Program That Facilitates Clinical Measurement of Ultrasound Carotid Intima–Media Thickness." *Journal of the American Society of Echocardiography* 18(3):244–251, 2005.
- Stein JH. "Carotid Intima-Media Thickness and Vascular Age: You Are Only as Old as Your Arteries Look." *Journal of the American Society of Echocardiography* 17(6):686–689, 2004.
- Umemura S, Arima H, Arima S, et al. "The Japanese Society of Hypertension Guidelines for the Management of Hypertension (JSH 2019)." *Hypertension Research* 42:1235–1481, 2019.
- Wilson PWF, D'Agostino RB, Levy D, Belanger AM, Silbershatz H, Kannel WB. "Prediction of Coronary Heart Disease Using Risk Factor Categories." *Circulation* 97(18):1837–1847, 1998.

## Adult Cardiac

- Adler AC, Nathanson BH, Raghunathan K, et al. "Misleading Indexed Hemodynamic Parameters: The Clinical Importance of Discordant BMI and BSA at Extremes of Weight." *Critical Care* 16(6):471, 2012.
- Akyüz Özkan E, Khosrashahi HE, Serin Hİ, et al. "Cardiac and Arterial Elastance and Myocardial Wall Stress in Children with Pectus Excavatum." *Interactive Cardiovascular and Thoracic Surgery* 23(1):4–8, 2016.
- Anderson B. *A Sonographer's Guide to the Assessment of Heart Disease*. Australia: MGA Graphics, 2014, 1st Edition (ISBN 978-0-9923222-0-5).
- Anderson B. *Echocardiography: The Normal Examination and Echocardiographic Measurements*. Australia: Echotext, 2017, 3rd Edition (ISBN 978-0-9923222-1-2).
- Araujo AQ, Araujo AQ. "Elucidating the B Bump on the Mitral Valve M-mode Echogram in Patients with Severe Left Ventricular Systolic Dysfunction." *International Journal of Cardiology* 95(1):7–12, 2004.
- Awasthy N, Radhakrishnan S. "Stepwise Evaluation of Left to Right Shunts by Echocardiography." *Indian Heart Journal* 65(2):201–218, 2013.
- Baumgartner H, Hung J, Bermejo J, et al. "Echocardiographic Assessment of Valve Stenosis: EAE/ASE Recommendations for Clinical Practice." *Journal of the American Society of Echocardiography* 22(1):1–23, 2009.
- Baumgartner H, Hung J, Bermejo J, et al. "Recommendations on the Echocardiographic Assessment of Aortic Valve Stenosis: A Focused Update from the European Association of Cardiovascular Imaging and the American Society of Echocardiography." *Journal of the American Society of Echocardiography* 30(4):372–392, 2017.
- Borow KM, Colan SD, Neumann A. "Altered Left Ventricular Mechanics in Patients with Valvular Aortic Stenosis and Coarction of the Aorta: Effects on Systolic Performance and Late Outcome." *Circulation* 72(3):515–522, 1985.
- Chung CS, Kovács SJ. "Consequences of Increasing Heart Rate on Deceleration Time, the Velocity-time Integral, and E/A." *American Journal of Cardiology* 97(1):130–136, 2006.
- Cohen MS, Eidem BW, Cetta F, et al. "Multimodality Imaging Guidelines of Patients with Transposition of the Great Arteries: A Report from the American Society of Echocardiography Developed in Collaboration with the Society for Cardiovascular Magnetic Resonance and the Society of Cardiovascular Computed Tomography." *Journal of the American Society of Echocardiography* 29(7):571–621, 2016.

- Cosansu K, Kilic H, Turer Cabbar A, et al. "Use of the Left Ventricular Internal Dimension at End-diastole and the E-point Septal Separation Ratio in the Prediction of the Left Ventricular Systolic Function in Patients with Midrange and Reduced Ejection Fractions: A Pilot Study." *Journal of Tehran University Heart Center* 14(4):171–176, 2019.
- Devereux RB, Reichek N. "Echocardiographic Determination of Left Ventricular Mass in Man. Anatomic Validation of the Method." *Circulation* 55(4):613–618, 1977.
- DeVore GR, Klas B, Satou G, et al. "Twenty-four Segment Transverse Ventricular Fractional Shortening: A New Technique to Evaluate Fetal Cardiac Function." *Journal of Ultrasound in Medicine* 37(5):1129–1141, 2018.
- Douglas PS, Reichek N, Plappert T, et al. "Comparison of Echocardiographic Methods for Assessment of Left Ventricular Shortening and Wall Stress." *Journal of the American College of Cardiology* 9(4):945–951, 1987.
- Duncan AM, Lim E, Clague J, et al. "Comparison of Segmental and Global Markers of Dyssynchrony in Predicting Clinical Response to Cardiac Resynchronization." *European Heart Journal* 27(20):2426–2432, 2006.
- Evangelista A, Garcia-Dorado D, Garcia del Castillo H, et al. "Cardiac Index Quantification by Doppler Ultrasound in Patients Without Left Ventricular Outflow Tract Abnormalities." *Journal of the American College of Cardiology* 25(3):710–716, 1995.
- Frommelt P, Lopez L, Dimas VV, et al. "Recommendations for Multimodality Assessment of Congenital Coronary Anomalies: A Guide from the American Society of Echocardiography: Developed in Collaboration with the Society for Cardiovascular Angiography and Interventions, Japanese Society of Echocardiography, and Society for Cardiovascular Magnetic Resonance." *Journal of the American Society of Echocardiography* 33(3):259–294, 2020.
- Gamaza-Chulián S, Díaz-Retamino E, Camacho-Freire S, et al. "Acceleration Time and Ratio of Acceleration Time to Ejection Time in Aortic Stenosis: New Echocardiographic Diagnostic Parameters." *Journal of the American Society of Echocardiography* 30(10):947–955, 2017.
- Gerhard-Herman M, Gardin JM, Jaff M, et al. "Guidelines for Noninvasive Vascular Laboratory Testing: A Report from the American Society of Echocardiography and the Society of Vascular Medicine and Biology." *Journal of the American Society of Echocardiography* 19(8):955–972, 2006.
- Goldstein SA, Evangelista A, Abbara S, et al. "Multimodality Imaging of Diseases of the Thoracic Aorta in Adults: From the American Society of Echocardiography and the European Association of Cardiovascular Imaging: Endorsed by the Society of Cardiovascular Computed Tomography and Society for Cardiovascular Magnetic Resonance." *Journal of the American Society of Echocardiography* 28(2):119–182, 2015.
- Hahn RT, Abraham T, Adams MS, et al. "Guidelines for Performing a Comprehensive Transesophageal Echocardiographic Examination: Recommendations from the American Society of Echocardiography and the Society of Cardiovascular Anesthesiologists." *Journal of the American Society of Echocardiography* 26(9):921–964, 2013.
- Hodges M, Halpern BL, Friesinger GC, et al. "Left Ventricular Preejection Period and Ejection Time in Patients with Acute Myocardial Infarction." *Circulation* 45(5):933–942, 1972.
- Intersocietal Accreditation Commission. *IAC Standards and Guidelines for Adult Echocardiography Accreditation*. Revised 4/27/2018.
- Iyer P, Evans N. "Re-evaluation of the Left Atrial to Aortic Root Ratio as a Marker of Patent Ductus Arteriosus." *Archives of Disease in Childhood. Fetal and Neonatal Edition* 70(2):F112–117, 1994.
- Jamal F, Szilard M, Kukulski T, et al. "Changes in Systolic and Postsystolic Wall Thickening During Acute Coronary Occlusion and Reperfusion in Closed-chest Pigs: Implications for the Assessment of Regional Myocardial Function." *Journal of the American Society of Echocardiography* 14(7):691–697, 2001.
- Jiamsripong P, Honda T, Reuss CS, et al. "Three Methods for Evaluation of Left Atrial Volume." *European Journal of Echocardiography* 9(3):351–355, 2008.
- Johri AM, Nambi V, Naqvi TZ, et al. "Recommendations for the Assessment of Carotid Arterial Plaque by Ultrasound for the Characterization of Atherosclerosis and Evaluation of Cardiovascular Risk: From the American Society of Echocardiography." *Journal of the American Society of Echocardiography* 33(8):917–933, 2020.
- Kanagala P, Arnold JR, Cheng ASH, et al. "Left Atrial Ejection Fraction and Outcomes in Heart Failure with Preserved Ejection Fraction." *International Journal of Cardiovascular Imaging* 36(1):101–110, 2020.
- Kansal S, Roitman D, Sheffield LT. "Interventricular Septal Thickness and Left Ventricular Hypertrophy. An Echocardiographic Study." *Circulation* 60(5):1058–1065, 1979.

- Klein AL, Abbara S, Agler DA, et al. "American Society of Echocardiography Clinical Recommendations for Multimodality Cardiovascular Imaging of Patients with Pericardial Disease: Endorsed by the Society for Cardiovascular Magnetic Resonance and Society of Cardiovascular Computed Tomography." *Journal of the American Society of Echocardiography* 26(9):965–1012, 2013.
- Lang RM, Badano LP, Mor-Avi V, et al. "Recommendations for Cardiac Chamber Quantification by Echocardiography in Adults: An Update from the American Society of Echocardiography and the European Association of Cardiovascular Imaging." *Journal of the American Society of Echocardiography* 28(1):1–39, 2015.
- Lang RM, Badano LP, Tsang W, et al. "EAE/ASE Recommendations for Image Acquisition and Display Using Three-dimensional Echocardiography." *Journal of the American Society of Echocardiography* 25(1):3–46, 2012.
- Lang RM, Bierig M, Devereux RB, et al. "Recommendations for Chamber Quantification." *European Journal of Echocardiography* 7(2):79–108, 2006.
- Lewis RP, Rittogers SE, Forester WF (Froester WF), et al. "A Critical Review of the Systolic Time Intervals." *Circulation* 56(2):146–158, 1977.
- López-Candales A, Edelman K. "Ratio of Right to Left Ventricular Ejection: A Pilot Study Using Doppler to Detect Interventricular Dyssynchrony." *Clinical Cardiology* 34(6):366–371, 2011.
- Matos J, Kronzon I, Panagopoulos G, et al. "Mitral Annular Plane Systolic Excursion as a Surrogate for Left Ventricular Ejection Fraction." *Journal of the American Society of Echocardiography* 25(9):969–974, 2012.
- Mertens HM, Mannebach H, Trieb G, et al. "Influence of Heart Rate on Systolic Time Intervals: Effects of Atrial Pacing versus Dynamic Exercise." *Clinical Cardiology* 4(1):22–27, 1981.
- Mertens L, Seri I, Marek J, et al. "Targeted Neonatal Echocardiography in the Neonatal Intensive Care Unit: Practice Guidelines and Recommendations for Training." *Journal of the American Society of Echocardiography* 24(10):1057–1078, 2011.
- Mitchell C, Rahko PS, Blauwet LA, et al. "Guidelines for Performing a Comprehensive Transthoracic Echocardiographic Examination in Adults: Recommendations from the American Society of Echocardiography." *Journal of the American Society of Echocardiography* 32(1):1–64, 2019.
- Mor-Avi V, Lang RM, Badano LP, et al. "Current and Evolving Echocardiographic Techniques for the Quantitative Evaluation of Cardiac Mechanics: ASE/EAE Consensus Statement on Methodology and Indications Endorsed by the Japanese Society of Echocardiography." *Journal of the American Society of Echocardiography* 24(3):277–313, 2011.
- Nagueh SF, Appleton CP, Gillebert TC, et al. "Recommendations for the Evaluation of Left Ventricular Diastolic Function by Echocardiography." *Journal of the American Society of Echocardiography* 22(2):107–133, 2009.
- Nagueh SF, Smiseth OA, Appleton CP, et al. "Recommendations for the Evaluation of Left Ventricular Diastolic Function by Echocardiography: An Update from the American Society of Echocardiography and the European Association of Cardiovascular Imaging." *Journal of the American Society of Echocardiography* 29(4):277–314, 2016.
- Nambi V, Chambless L, He M, et al. "Common Carotid Artery Intima-media Thickness is as Good as Carotid Intima-media Thickness of All Carotid Artery Segments in Improving Prediction of Coronary Heart Disease Risk in the Atherosclerosis Risk in Communities (ARIC) Study." *European Heart Journal* 33(2):183–190, 2012.
- Nicoara A, Skubas N, Ad N, et al. "Guidelines for the Use of Transesophageal Echocardiography to Assist with Surgical Decision-making in the Operating Room: A Surgery-based Approach: From the American Society of Echocardiography in Collaboration with the Society of Cardiovascular Anesthesiologists and the Society of Thoracic Surgeons." *Journal of the American Society of Echocardiography* 33(6):692–734, 2020.
- Ommen SR, Nishimura RA, Appleton CP, et al. "Clinical Utility of Doppler Echocardiography and Tissue Doppler Imaging in the Estimation of Left Ventricular Filling Pressures: A Comparative Simultaneous Doppler-catheterization Study." *Circulation* 102(15):1788–1794, 2000.
- Orsinelli DA, Armour A, De Cara J, et al. *The American Society of Echocardiography Recommendations for Cardiac Chamber Quantification in Adults: A Quick Reference Guide from the ASE Workflow and Lab Management Task Force*. 2018.
- Otto CM. "Valvular Aortic Stenosis: Disease Severity and Timing of Intervention." *Journal of the American College of Cardiology* 47(11) 2141–2151, 2006.
- Pellikka PA, Arruda-Olson A, Chaudhry FA, et al. "Guidelines for Performance, Interpretation, and Application of Stress Echocardiography in Ischemic Heart Disease: From the American Society of Echocardiography." *Journal of the American Society of Echocardiography* 33(1):1–41, 2020.
- Picard MH, Adams D, Bierig SM, et al. "American Society of Echocardiography Recommendations for Quality Echocardiography Laboratory Operations." *Journal of the American Society of Echocardiography* 24(1):1–10, 2011.

- Picard MH, Popp RL, Weyman AE. "Assessment of Left Ventricular Function by Echocardiography: A Technique in Evolution." *Journal of the American Society of Echocardiography* 21(1):14–21, 2008.
- Pombo JF, Troy BL, Russell RO Jr. "Left Ventricular Volumes and Ejection Fraction by Echocardiography." *Circulation* 43(4):480–490, 1971.
- Porter TR, Abdelmoneim S, Belcik JT, et al. "Guidelines for the Cardiac Sonographer in the Performance of Contrast Echocardiography: A Focused Update from the American Society of Echocardiography." *Journal of the American Society of Echocardiography* 27(8):797–810, 2014.
- Porter TR, Mulvagh SL, Abdelmoneim SS, et al. "Clinical Applications of Ultrasonic Enhancing Agents in Echocardiography: 2018 American Society of Echocardiography Guidelines Update." *Journal of the American Society of Echocardiography* 31(3):241–274, 2018.
- Quiñones MA, Otto CM, Stoddard M, et al. "Recommendations for Quantification of Doppler Echocardiography: A Report from the Doppler Quantification Task Force of the Nomenclature and Standards Committee of the American Society of Echocardiography." *Journal of the American Society of Echocardiography* 15(2):167–184, 2002.
- Quinones MA, Waggoner AD, Reduto LA, et al. "A New, Simplified and Accurate Method for Determining Ejection Fraction with Two-dimensional Echocardiography." *Circulation* 64(4):744–753, 1981.
- Reant P, Dijos M, Donal E, et al. "Systolic Time Intervals as Simple Echocardiographic Parameters of Left Ventricular Systolic Performance: Correlation with Ejection Fraction and Longitudinal Two-dimensional Strain." *European Journal of Echocardiography* 11(10):834–844, 2010.
- Reeves ST, Finley AC, Skubas NJ, et al. "Basic Perioperative Transesophageal Echocardiography Examination: A Consensus Statement of the American Society of Echocardiography and the Society of Cardiovascular Anesthesiologists." *Journal of the American Society of Echocardiography* 26(5):443–456, 2013.
- Reichek N, Wilson J, St John Sutton M, et al. "Noninvasive Determination of Left Ventricular End-systolic Stress: Validation of the Method and Initial Application." *Circulation* 65(1):99–108, 1982.
- Riggs T, Hirschfeld S, Borkat G, et al. "Assessment of the Pulmonary Vascular Bed by Echocardiographic Right Ventricular Systolic Time Intervals." *Circulation* 57(5):939–947, 1978.
- Rudski LG, Lai WW, Afilalo J, et al. "Guidelines for the Echocardiographic Assessment of the Right Heart in Adults: A Report from the American Society of Echocardiography." *Journal of the American Society of Echocardiography* 23(7):685–713, 2010.
- Rychik J, Ayres N, Cuneo B, et al. "American Society of Echocardiography Guidelines and Standards for Performance of the Fetal Echocardiogram." *Journal of the American Society of Echocardiography* 17(7):803–810, 2004.
- Saric M, Armour AC, Arnaout MS, et al. "Guidelines for the Use of Echocardiography in the Evaluation of a Cardiac Source of Embolism." *Journal of the American Society of Echocardiography* 29(1):1–42, 2016.
- Silvestry FE, Kerber RE, Brook MM, et al. "Echocardiography-guided Interventions." *Journal of the American Society of Echocardiography* 22(3):213–231, 2009.
- Simpson J, Lopez L, Acar P, et al. "Three-dimensional Echocardiography in Congenital Heart Disease: An Expert Consensus Document from the European Association of Cardiovascular Imaging and the American Society of Echocardiography." *Journal of the American Society of Echocardiography* 30(1):1–27, 2017.
- Solomon SD (Editor). *Essential Echocardiography: A Practical Handbook with DVD*. New Jersey: Humana Press, 2007 Edition (eISBN 1-58829-322-0).
- St John Sutton MG, Plappert TA, Hirshfeld JW, et al. "Assessment of Left Ventricular Mechanics in Patients with Asymptomatic Aortic Regurgitation: A Two-dimensional Echocardiographic Study." *Circulation* 69(2):259–268, 1984.
- Teng WH, McCall PJ, Shelley BG. "The Utility of Eccentricity Index as a Measure of the Right Ventricular Function in a Lung Resection Cohort." *Journal of Cardiovascular Echography* 29(3):103–110, 2019.
- Thomas JD, Weyman AE. "Doppler Mitral Pressure Half-time: A Clinical Tool in Search of Theoretical Justification." *Journal of the American College of Cardiology* 10(4):923–929, 1987.
- Valente AM, Cook S, Festa P, et al. "Multimodality Imaging Guidelines for Patients with Repaired Tetralogy of Fallot: A Report from the American Society of Echocardiography: Developed in Collaboration with the Society for Cardiovascular Magnetic Resonance and the Society for Pediatric Radiology." *Journal of the American Society of Echocardiography* 27(2):111–141, 2014.
- Weiss MB, Ellis K, Sciacca RR, et al. "Myocardial Blood Flow in Congestive and Hypertrophic Cardiomyopathy: Relationship to Peak Wall Stress and Mean Velocity of Circumferential Fiber Shortening." *Circulation* 54(3):484–494, 1976.

- Weissler AM, Harris LC, White GD. "Left-ventricular Ejection Time Index in Man." *Journal of Applied Physiology* 18:919–923, 1963.
- Whitener GB, Shanahan PC, Wolf BJ, et al. "Grading Aortic Valve Stenosis with Dimensionless Index during Pre-cardiopulmonary Bypass Transesophageal Echocardiography: A Comparison with Transthoracic Echocardiography." *Journal of Cardiothoracic and Vascular Anesthesia* 33(9):2376–2384, 2019.
- Zamorano JL, Badano LP, Bruce C, et al. "EAE/ASE Recommendations for the Use of Echocardiography in New Transcatheter Interventions for Valvular Heart Disease." *Journal of the American Society of Echocardiography* 24(9):937–965, 2011.
- Zoghbi WA, Adams D, Bonow RO, et al. "Recommendations for Noninvasive Evaluation of Native Valvular Regurgitation: A Report from the American Society of Echocardiography Developed in Collaboration with the Society for Cardiovascular Magnetic Resonance." *Journal of the American Society of Echocardiography* 30(4):303–371, 2017.
- Zoghbi WA, Chambers JB, Dumesnil JG, et al. "Recommendations for Evaluation of Prosthetic Valves with Echocardiography and Doppler Ultrasound." *Journal of the American Society of Echocardiography* 22(9):975–1014, 2009.
- Zoghbi WA, Enriquez-Sarano M, Foster E, et al. "Recommendations for Evaluation of the Severity of Native Valvular Regurgitation with Two-dimensional and Doppler Echocardiography." *Journal of the American Society of Echocardiography* 16(7):777–802, 2003.

## Pediatric Cardiac

- Lai WW, Geva T, Shirali GS, et al. "Guidelines and Standards for Performance of a Pediatric Echocardiogram: A Report from the Task Force of the Pediatric Council of the American Society of Echocardiography." *Journal of the American Society of Echocardiography* 19(12):1413–1430, 2006.
- Lopez L, Colan SD, Frommelt PC, et al. "Recommendations for Quantification Methods During the Performance of a Pediatric Echocardiogram: A Report from the Pediatric Measurements Writing Group of the American Society of Echocardiography Pediatric and Congenital Heart Disease Council." *Journal of the American Society of Echocardiography* 23(5):465–495, 2010.
- Roche SL, Vogel M, Pitkänen O, et al. "Isovolumic Acceleration at Rest and During Exercise in Children Normal Values for the Left Ventricle and First Noninvasive Demonstration of Exercise-induced Force-frequency Relationships." *Journal of the American College of Cardiology* 57(9):1100–1107, 2011.

## 2D Heart AI and 4D Heart AI

- Aase SA, Torp H, Støylen A. "Aortic Valve Closure: Relation to Tissue Velocities by Doppler and Speckle Tracking in Normal Subjects." *European Journal of Echocardiography* 9(4):555–559, 2008.
- Badano LP, Koliás TJ, Muraru D, et al. "Standardization of Left Atrial, Right Ventricular, and Right Atrial Deformation Imaging Using Two-dimensional Speckle Tracking Echocardiography: A Consensus Document of the EACVI/ASE/Industry Task Force to Standardize Deformation Imaging." *European Heart Journal. Cardiovascular Imaging* 19(6):591–600, 2018.
- Candan O, Gecmen C, Bayam E, et al. "Mechanical Dispersion and Global Longitudinal Strain by Speckle Tracking Echocardiography: Predictors of Appropriate Implantable Cardioverter Defibrillator Therapy in Hypertrophic Cardiomyopathy." *Echocardiography* 34(6):835–842, 2017.
- Celebi AS, Yalcin H, Yalcin F. "Current Cardiac Imaging Techniques for Detection of Left Ventricular Mass." *Cardiovascular Ultrasound* 8:19, 2010.
- Douglas PS, Carabello BA, Lang RM, et al. "2019 ACC/AHA/ASE Key Data Elements and Definitions for Transthoracic Echocardiography: A Report of the American College of Cardiology/American Heart Association Task Force on Clinical Data Standards (Writing Committee to Develop Clinical Data Standards for Transthoracic Echocardiography) and the American Society of Echocardiography." *Journal of the American Society of Echocardiography* 32(9):1161–1248, 2019.
- Kanagala P, Arnold JR, Cheng ASH, et al. "Left Atrial Ejection Fraction and Outcomes in Heart Failure with Preserved Ejection Fraction." *The International Journal of Cardiovascular Imaging* 36(1):101–110, 2020.
- Kovalova S, Necas J, Vespalec J. "What is a 'Normal' Right Ventricle?" *European Journal of Echocardiography* 7(4):293–297, 2006.
- Lang RM, Badano LP, Mor-Avi V, et al. "Recommendations for Cardiac Chamber Quantification by Echocardiography in Adults: An Update from the American Society of Echocardiography and the European Association of Cardiovascular Imaging." *Journal of the American Society of Echocardiography* 28(1):1–39.e14, 2015.
- Mouratoglou SA, Dimopoulos K, Kamperidis V, et al. "Right Atrial Function Predicts Clinical Outcome in Patients with Precapillary Pulmonary Hypertension." *Journal of the American Society of Echocardiography* 31(10):1137–1145, 2018.
- Rudski LG, Lai WW, Afilalo J, et al. "Guidelines for the Echocardiographic Assessment of the Right Heart in Adults: A Report from the American Society of Echocardiography." *Journal of the American Society of Echocardiography* 23(7):685–713, 2010.
- Solomon SD (Editor). *Essential Echocardiography: A Practical Handbook with DVD* New Jersey: Humana Press, 2007 Edition (eISBN 1-58829-322-0).
- Zhang C, Chen T. "Efficient Feature Extraction for 2D/3D Objects in Mesh Representation." *Proceedings 2001 International Conference on Image Processing (Cat. No.01CH37205)*, pp. 935–38 vol. 3, doi: 10.1109/ICIP.2001.958278. Thessaloniki, Greece, 2001.

## Fetal Echo Clinical References

### Fractional Shortening

Wladimiroff JW, McGhie JS. "M-mode Ultrasonic Assessment of Fetal Cardiovascular Dynamics." *British Journal of Obstetrics and Gynaecology* 88:1241–1245, 1981.

### Cardiothoracic Ratio

Chaoui R, Bollmann R, Goldner B, Heling KS, Tennstedt C. "Fetal Cardiomegaly: Echocardiographic Findings and Outcome in 19 Cases." *Fetal Diagnosis and Therapy* 9:92–104, 1994.

### Mean Pressure Gradient

Currie PJ, Seward JB, Chan KL, Fyfe DA, Hagler DJ, Mair DD, Reeder GS, Nishimura RA, Tajik AJ. "Continuous Wave Doppler Determination of Right Ventricular Pressure: A Simultaneous Doppler-catheterization Study in 127 Patients." *Journal of the American College of Cardiology* 6(4):750–756, 1985.

### Mitral Valve Peak E Wave Velocity to Peak A Wave Velocity Ratio

Appleton CP, Liv KH, Popp RL. "Relation of Transmitral Flow Velocity Patterns to Left Ventricular Diastolic Function: New Insights from a Combined Hemodynamic and Doppler Echocardiographic Study." *Journal of the American College of Cardiology* 12(2):426–440, 1988.

### Peak Pressure Gradient

Currie PJ, Seward JB, Chan KL, Fyfe DA, Hagler DJ, Mair DD, Reeder GS, Nishimura RA, Tajik AJ. "Continuous Wave Doppler Determination of Right Ventricular Pressure: A Simultaneous Doppler-catheterization Study in 127 Patients." *Journal of the American College of Cardiology* 6(4):750–756, 1985.

### Tei Index (Myocardial Performance Index)

Tsutsumi T, Ishii M, Eto G, Hota M, Kato H. "Serial Evaluation for Myocardial Performance in Fetuses and Neonates Using a New Doppler Index." *Pediatrics International* 41(6):722–727, 1999.

### Z-Score Calculations

#### Boston Children's Hospital:

McElhinney DB, Marshall AC, Wilkins-Haug LE, Brown DW, Benson CB, Silva V, et al. "Predictors of Technical Success and Postnatal Biventricular Outcome After In-Utero Aortic Valvuloplasty for Aortic Stenosis with Evolving Hypoplastic Left Heart Syndrome." *Circulation* 120:1482–1490, 2009.

#### Royal Brompton Hospital:

Pasquini L, Mellander M, Seale A, Matsui H, Roughton M, Ho SY, Gardiner HM. "Z-scores of the Fetal Aortic Isthmus and Duct: An Aid to Assessing Arch Hypoplasia." *Ultrasound in Obstetrics and Gynecology* 29(6):628–633, 2007.

Schneider C, McCrindle BW, Carvalho JS, Hornberger LK, McCarthy KP, Daubeney PE.

"Development of Z-scores for Fetal Cardiac Dimensions from Echocardiography." *Ultrasound in Obstetrics and Gynecology* 26(6):599–605, 2005.

## Obstetric Clinical References

### Simple Gestational Age Calculations

#### Abdominal Circumference

Hadlock FP, Deter RL, Harrist RB, Park SK. "Estimating Fetal Age: Computer-Assisted Analysis of Multiple Fetal Growth Parameters." *Radiology* 152(2):497–502, 1984.

Lasser DM, Peisner DB, Vollebergh J, Timor-Tritsch I. "First-trimester Fetal Biometry Using Transvaginal Sonography." *Ultrasound in Obstetrics and Gynecology* 3(2):104–108, 1993.

Merz E. *Ultrasound in Gynecology and Obstetrics*. Stuttgart and New York: Thieme Medical Publishers, Inc., 1991, 1st Edition (ISBN 0-865-77376-9); p. 312–326.

#### ASUM 2003:

Westerway SC. "Ultrasonic Fetal Measurements for an Australian Population." 2003.

Adapted from Westerway SC, Davison A, Cowell S. "Ultrasonic Fetal Measurements: New Australian Standards for the New Millennium." *Australian and New Zealand Journal of Obstetrics and Gynaecology* 40(3):297–302, 2000.

#### JSUM 2003:

Japan Society of Ultrasonics in Medicine. "Standardization of Fetometry and Official Announcement of Diagnostic Guidelines." *Journal of Medical Ultrasonics* 30(3):415–440, 2003.

### Anterior-Posterior Trunk Diameter Multiplied by Transverse Trunk Diameter

#### Tokyo:

Shinozuka N, Okai T, Mizuno M. "Chapter 80. Fetal Measurements." *Obstetrics and Gynecology* Shindan To Iryo Sha Inc., 1989, Vol. 56 Supplement, p. 370–380.

### Binocular Distance

Jeanty P, Cantraine F, Cousaert E, Romero R, Hobbins JC. "The Binocular Distance: A New Way to Estimate Fetal Age." *Journal of Ultrasound in Medicine* 3:241–243, 1984.

Tongsong T, Wanapirak C, Jesadapornchai S, Tathayathikom E. "Fetal Binocular Distance as a Predictor of Menstrual Age." *International Journal of Gynecology and Obstetrics* 38(2):87–91, 1992.

## Biparietal Diameter

Hadlock FP, Deter RL, Carpenter RJ, Park SK. "Estimating Fetal Age: Effect of Head Shape on BPD." *American Journal of Roentgenology* 137(1):83–85, 1981.

Hansmann M, Hackelöer B-J, Staudach A. *Ultrasound Diagnosis in Obstetrics and Gynecology*. New York: Springer-Verlag, 1986, English Edition (ISBN 0-387-15384-9); p. 440–441.

Jeanty P, Romero R. *Obstetrical Ultrasound*. New York: McGraw-Hill Book Company, 1984, (ISBN ISBN 0-070-32319-4); p. 58.

Lasser DM, Peisner DB, Vollebergh J, Timor-Tritsch I. "First-trimester Fetal Biometry Using Transvaginal Sonography." *Ultrasound in Obstetrics and Gynecology* 3(2):104–108, 1993.

Merz E. *Ultrasound in Gynecology and Obstetrics*. Stuttgart and New York: Thieme Medical Publishers, Inc., 1991, 1st Edition (ISBN 0-865-77376-9); p. 312–326.

Rempen A, Chaoui R, Kozłowski P, Häusler M, Terinde R, Wisser J. "Standards zur Ultraschalluntersuchung in der Frühschwangerschaft." *Der Frauenarzt* 42:327–331, 2001.

### ASUM 2003:

Westerway SC. "Ultrasonic Fetal Measurements for an Australian Population." 2003.

Adapted from Westerway SC, Davison A, Cowell S. "Ultrasonic Fetal Measurements: New Australian Standards for the New Millennium." *Australian and New Zealand Journal of Obstetrics and Gynaecology* 40(3):297–302, 2000.

### Chitty (Outer to Inner):

Altman DG, Chitty LS. "New Charts for Ultrasound Dating of Pregnancy." *Ultrasound in Obstetrics and Gynecology* 10(3):174–191, 1997.

### Chitty (Outer to Outer):

Altman DG, Chitty LS. "New Charts for Ultrasound Dating of Pregnancy." *Ultrasound in Obstetrics and Gynecology* 10(3):174–191, 1997.

### JSUM 2003:

Japan Society of Ultrasonics in Medicine. "Standardization of Fetometry and Official Announcement of Diagnostic Guidelines." *Journal of Medical Ultrasonics* 30(3):415–440, 2003.

### Osaka:

Mineo A. "IUGR Diagnosis and Treatment." *Perinatal Care* 9(5):37–52 (407–422), 1990.

### Verburg (Outer to Outer):

Verburg BO, Steegers EA, De Ridder M, Snijders RJ, Smith E, Hofman A, Moll HA, Jaddoe VW, Wittman JC. "New Charts for Ultrasound Dating of Pregnancy and Assessment of Fetal Growth: Longitudinal Data From a Population-based Cohort Study." *Ultrasound in Obstetrics and Gynecology* 31(4):388–396, 2008.

## Cerebellum, Transverse Cerebellar Diameter

Hill LM, Guzick D, Fries J, Hixson J, Rivello D. "The Transverse Cerebellar Diameter in Estimating Gestational Age in the Large for Gestational Age-Fetus." *Obstetrics and Gynecology* 75(6):981–985, 1990.

## Crown Rump Length

Hadlock FP, Shah YP, Kanon DJ, Lindsey JV. "Fetal Crown-Rump Length: Reevaluation of Relation to Menstrual Age (5–18 weeks) with High-Resolution Real-Time US." *Radiology* 182(2):501–505, 1992.

Hansmann M, Hackelöer B-J, Staudach A. *Ultrasound Diagnosis in Obstetrics and Gynecology*. New York: Springer-Verlag, 1986, English Edition (ISBN 0-387-15384-9); p. 439.

Lasser DM, Peisner DB, Vollebergh J, Timor-Tritsch I. "First-trimester Fetal Biometry Using Transvaginal Sonography." *Ultrasound in Obstetrics and Gynecology* 3(2):104–108, 1993.

Rempen A, Chaoui R, Kozłowski P, Häusler M, Terinde R, Wisser J. "Standards zur Ultraschalluntersuchung in der Frühschwangerschaft." *Der Frauenarzt* 42:327–331, 2001.

Robinson HP, Fleming JE. "A Critical Evaluation of Sonar 'Crown-rump Length' Measurements." *British Journal of Obstetrics and Gynaecology* 82(9):702–710, 1975.

Verburg BO, Steegers EA, De Ridder M, Snijders RJ, Smith E, Hofman A, Moll HA, Jaddoe VW, Witteman JC. "New Charts for Ultrasound Dating of Pregnancy and Assessment of Fetal Growth: Longitudinal Data From a Population-based Cohort Study." *Ultrasound in Obstetrics and Gynecology* 31(4):388–396, 2008.

### ASUM 2003:

Westerway SC. "Ultrasonic Fetal Measurements for an Australian Population." 2003. Adapted from Westerway SC, Davison A, Cowell S. "Ultrasonic Fetal Measurements: New Australian Standards for the New Millennium." *Australian and New Zealand Journal of Obstetrics and Gynaecology* 40(3):297–302, 2000.

### INTERGROWTH-21st:

Papageorghiou AT, Kennedy SH, Salomon LJ, Ohuma EO, et al. "International Standards for Early Fetal Size and Pregnancy Dating Based on Ultrasound Measurement of Crown-rump Length in the First Trimester of Pregnancy." *Ultrasound in Obstetrics and Gynecology* 44(6):641–648, 2014.

### JSUM 2003:

Japan Society of Ultrasonics in Medicine. "Standardization of Fetometry and Official Announcement of Diagnostic Guidelines." *Journal of Medical Ultrasonics* 30(3):415–440, 2003.

### Osaka:

Mineo A. "IUGR Diagnosis and Treatment." *Perinatal Care* 9(5):37–52 (407–422), 1990.

### Tokyo:

Masuda H, Shinozuka N, Okai T, Mizuno M. "Diagnosis of the Week of Pregnancy and Prognosis." *Perinatal Care* 8:43–50 (719–726).

## Estimated Fetal Weight

### JSUM 2003:

Japan Society of Ultrasonics in Medicine. "Standardization of Fetometry and Official Announcement of Diagnostic Guidelines." *Journal of Medical Ultrasonics* 30(3):415–440, 2003.

### Osaka:

Mineo A. "IUGR Diagnosis and Treatment." *Perinatal Care* 9(5):37–52 (407–422), 1990.

### Tokyo:

Masuda H, Shinozuka N, Okai T, Mizuno M. "Diagnosis of the Week of Pregnancy and Prognosis." *Perinatal Care* 8:43–50 (719–726).

## Femur Length

- Altman DG, Chitty LS. "New Charts for Ultrasound Dating of Pregnancy." *Ultrasound in Obstetrics and Gynecology* 10(3):174–191, 1997.
- Hadlock FP, Deter RL, Harrist RB, Park SK. "Estimating Fetal Age: Computer-Assisted Analysis of Multiple Fetal Growth Parameters." *Radiology* 152(2):497–502, 1984.
- Jeanty P, Rodesch F, Delbeke D, Dumont JE. "Estimation of Gestational Age from Measurements of Fetal Long Bones." *Journal of Ultrasound in Medicine* 3(2):75–79, 1984.
- Merz E. *Ultrasound in Gynecology and Obstetrics*. Stuttgart and New York: Thieme Medical Publishers, Inc., 1991, 1st Edition (ISBN 0-865-77376-9); p. 312–326.
- Warda AH, Deter RL, Rossavik IK, Carpenter RJ, Hadlock FP. "Fetal Femur Length: A Critical Re-evaluation of Relationship to Menstrual Age." *Obstetrics and Gynecology*, 66(1):69–75, 1985.
- ASUM 2003:**
- Westerway SC. "Ultrasonic Fetal Measurements for an Australian Population." 2003.  
Adapted from Westerway SC, Davison A, Cowell S. "Ultrasonic Fetal Measurements: New Australian Standards for the New Millennium." *Australian and New Zealand Journal of Obstetrics and Gynaecology* 40(3):297–302, 2000.
- JSUM 2003:**
- Japan Society of Ultrasonics in Medicine. "Standardization of Fetometry and Official Announcement of Diagnostic Guidelines." *Journal of Medical Ultrasonics* 30(3):415–440, 2003.
- Osaka:**
- Mineo A. "IUGR Diagnosis and Treatment." *Perinatal Care* 9(5):37–52 (407–422), 1990.
- Tokyo:**
- Shinozuka N, Okai T, Mizuno M. "Chapter 80. Fetal Measurements." *Obstetrics and Gynecology* Shindan To Iryo Sha Inc., 1989, Vol. 56 Supplement, p. 370–380.

## Fetal Trunk Area

- Osaka:**
- Mineo A. "IUGR Diagnosis and Treatment." *Perinatal Care* 9(5):37–52 (407–422), 1990.

## Foot Length

- Mercer BM, Sklar S, Shariatmadar A, Gillieson MS, Dalton ME. "Fetal Foot Length as a Predictor of Gestational Age." *American Journal of Obstetrics and Gynecology* 156(2):350–355, 1987.

## Gestational Sac Diameter

- Rempen A. "Biometrie in der Frühgravidität (I. Trimenon) (Biometry in Early Pregnancy [1st Trimester])." *Der Frauenarzt* 32(4):425–430, 1991.
- Tokyo:**
- Masuda H, Shinozuka N, Okai T, Mizuno M. "Diagnosis of the Week of Pregnancy and Prognosis." *Perinatal Care* 8:43–50 (719–726).

## Head Circumference

Altman DG, Chitty LS. "New Charts for Ultrasound Dating of Pregnancy." *Ultrasound in Obstetrics and Gynecology* 10(3):174–191, 1997.

Hadlock FP, Deter RL, Harrist RB, Park SK. "Estimating Fetal Age: Computer-Assisted Analysis of Multiple Fetal Growth Parameters." *Radiology* 152(2):497–502, 1984.

Hansmann M, Hackelöer B-J, Staudach A. *Ultrasound Diagnosis in Obstetrics and Gynecology*. New York: Springer-Verlag, 1986, English Edition (ISBN 0-387-15384-9); p. 440–441.

Lasser DM, Peisner DB, Vollebergh J, Timor-Tritsch I. "First-trimester Fetal Biometry Using Transvaginal Sonography." *Ultrasound in Obstetrics and Gynecology* 3(2):104–108, 1993.

Merz E. *Ultrasound in Gynecology and Obstetrics*. Stuttgart and New York: Thieme Medical Publishers, Inc., 1991, 1st Edition (ISBN 0-865-77376-9); p. 312–326.

### ASUM 2003:

Westerway SC. "Ultrasonic Fetal Measurements for an Australian Population." 2003.  
Adapted from Westerway SC, Davison A, Cowell S. "Ultrasonic Fetal Measurements: New Australian Standards for the New Millennium." *Australian and New Zealand Journal of Obstetrics and Gynaecology* 40(3):297–302, 2000.

## Humerus Length

Jeanty P, Rodesch F, Delbeke D, Dumont JE. "Estimation of Gestational Age from Measurements of Fetal Long Bones." *Journal of Ultrasound in Medicine* 3(2):75–79, 1984.

### ASUM 2003:

Westerway SC. "Ultrasonic Fetal Measurements for an Australian Population." 2003.  
Adapted from Westerway SC, Davison A, Cowell S. "Ultrasonic Fetal Measurements: New Australian Standards for the New Millennium." *Australian and New Zealand Journal of Obstetrics and Gynaecology* 40(3):297–302, 2000.

### Osaka:

Mineo A. "IUGR Diagnosis and Treatment." *Perinatal Care* 9(5):37–52 (407–422), 1990.

## Mean Sac Diameter

Rempen A. "Biometrie in der Frühgravidität (I. Trimenon) (Biometry in Early Pregnancy [1st Trimester])." *Der Frauenarzt* 32(4):425–430, 1991.

## Occipital Frontal Diameter

### ASUM 2003:

Westerway SC. "Ultrasonic Fetal Measurements for an Australian Population." 2003.  
Adapted from Westerway SC, Davison A, Cowell S. "Ultrasonic Fetal Measurements: New Australian Standards for the New Millennium." *Australian and New Zealand Journal of Obstetrics and Gynaecology* 40(3):297–302, 2000.

## Tibia Length

Jeanty P, Rodesch F, Delbeke D, Dumont JE. "Estimation of Gestational Age from Measurements of Fetal Long Bones." *Journal of Ultrasound in Medicine* 3(2):75–79, 1984.

## Ulna Length

Jeanty P, Rodesch F, Delbeke D, Dumont JE. "Estimation of Gestational Age from Measurements of Fetal Long Bones." *Journal of Ultrasound in Medicine* 3(2):75–79, 1984.

## **Composite Gestational Age Calculations**

### **Abdominal Circumference, Femur Length**

Hadlock FP, Deter RL, Harrist RB, Park SK. "Estimating Fetal Age: Computer-Assisted Analysis of Multiple Fetal Growth Parameters." *Radiology* 152(2):497–502, 1984.

### **Biparietal Diameter, Abdominal Circumference**

Hadlock FP, Deter RL, Harrist RB, Park SK. "Estimating Fetal Age: Computer-Assisted Analysis of Multiple Fetal Growth Parameters." *Radiology* 152(2):497–502, 1984.

### **Biparietal Diameter, Abdominal Circumference, Femur Length**

Hadlock FP, Deter RL, Harrist RB, Park SK. "Estimating Fetal Age: Computer-Assisted Analysis of Multiple Fetal Growth Parameters." *Radiology* 152(2):497–502, 1984.

### **Biparietal Diameter, Femur Length**

Hadlock FP, Deter RL, Harrist RB, Park SK. "Estimating Fetal Age: Computer-Assisted Analysis of Multiple Fetal Growth Parameters." *Radiology* 152(2):497–502, 1984.

### **Biparietal Diameter, Head Circumference**

Hadlock FP, Deter RL, Harrist RB, Park SK. "Estimating Fetal Age: Computer-Assisted Analysis of Multiple Fetal Growth Parameters." *Radiology* 152(2):497–502, 1984.

### **Biparietal Diameter, Head Circumference, Abdominal Circumference**

Hadlock FP, Deter RL, Harrist RB, Park SK. "Estimating Fetal Age: Computer-Assisted Analysis of Multiple Fetal Growth Parameters." *Radiology* 152(2):497–502, 1984.

### **Biparietal Diameter, Head Circumference, Abdominal Circumference, Femur Length**

Hadlock FP, Deter RL, Harrist RB, Park SK. "Estimating Fetal Age: Computer-Assisted Analysis of Multiple Fetal Growth Parameters." *Radiology* 152(2):497–502, 1984.

### **Biparietal Diameter, Head Circumference, Femur Length**

Hadlock FP, Deter RL, Harrist RB, Park SK. "Estimating Fetal Age: Computer-Assisted Analysis of Multiple Fetal Growth Parameters." *Radiology* 152(2):497–502, 1984.

### **Head Circumference, Abdominal Circumference**

Hadlock FP, Deter RL, Harrist RB, Park SK. "Estimating Fetal Age: Computer-Assisted Analysis of Multiple Fetal Growth Parameters." *Radiology* 152(2):497–502, 1984.

### **Head Circumference, Abdominal Circumference, Femur Length**

Hadlock FP, Deter RL, Harrist RB, Park SK. "Estimating Fetal Age: Computer-Assisted Analysis of Multiple Fetal Growth Parameters." *Radiology* 152(2):497–502, 1984.

### **Head Circumference, Femur Length**

Hadlock FP, Deter RL, Harrist RB, Park SK. "Estimating Fetal Age: Computer-Assisted Analysis of Multiple Fetal Growth Parameters." *Radiology* 152(2):497–502, 1984.

### **Estimated Fetal Weight Calculations**

#### **Abdominal Circumference, Femur Length**

Hadlock FP, Harrist RB, Sharman RS, Deter RL, Park SK. "Estimation of Fetal Weight with the Use of Head, Body, and Femur Measurements – A Prospective Study." *American Journal of Obstetrics and Gynecology* 151(3):333–337, 1985.

#### **Biparietal Diameter, Abdominal Circumference**

Merz E. *Ultrasound in Gynecology and Obstetrics*. Stuttgart and New York: Thieme Medical Publishers, Inc., 1991, 1st Edition (ISBN 0-865-77376-9); p. 165.

Shepard MJ, Richards VA, Berkowitz RL, Warsof SL, Hobbins JC. "An Evaluation of Two Equations for Predicting Fetal Weight by Ultrasound." *American Journal of Obstetrics and Gynecology* 142(1):47–54, 1982.

#### **Biparietal Diameter, Abdominal Circumference, Femur Length**

Hadlock FP, Harrist RB, Sharman RS, Deter RL, Park SK. "Estimation of Fetal Weight with the Use of Head, Body, and Femur Measurements – A Prospective Study." *American Journal of Obstetrics and Gynecology* 151(3):333–337, 1985.

#### **JSUM 2003:**

Japan Society of Ultrasonics in Medicine. "Standardization of Fetometry and Official Announcement of Diagnostic Guidelines." *Journal of Medical Ultrasonics* 30(3):415–440, 2003.

### **Biparietal Diameter, Anterior-Posterior Transverse Diameter, Transverse Trunk Diameter, Femur Length**

#### **JSUM 2003:**

Japan Society of Ultrasonics in Medicine. "Standardization of Fetometry and Official Announcement of Diagnostic Guidelines." *Journal of Medical Ultrasonics* 30(3):415–440, 2003.

#### **Tokyo:**

Shinozuka N, Okai T, Kohzuma S, Mukubo M, Shih CT, Maeda T, Kuwabara Y, Mizuno M. "Formulas for Fetal Weight Estimation by Ultrasound Measurements Based on Neonatal Specific Gravities and Volumes." *American Journal of Obstetrics and Gynecology* 157(5):1140–1145, 1987.

### **Biparietal Diameter, Fetal Trunk Area, Femur Length**

#### **Osaka:**

Aoki M, Yamada M. "Examining Fetal Growth." *Obstetrics and Gynecology* 47(5):547–556, 1983.

### **Biparietal Diameter, Head Circumference, Abdominal Circumference, Femur Length**

Hadlock FP, Harrist RB, Sharman RS, Deter RL, Park SK. "Estimation of Fetal Weight with the Use of Head, Body, and Femur Measurements – A Prospective Study." *American Journal of Obstetrics and Gynecology* 151(3):333–337, 1985.

### **Biparietal Diameter, Transverse Trunk Diameter**

Hansmann M, Hackelöer B-J, Staudach A. *Ultrasound Diagnosis in Obstetrics and Gynecology*. New York: Springer-Verlag, 1986, English Edition (ISBN 0-387-15384-9); p. 154.

### **Head Circumference, Abdominal Circumference, Femur Length**

Hadlock FP, Harrist RB, Sharman RS, Deter RL, Park SK. "Estimation of Fetal Weight with the Use of Head, Body, and Femur Measurements – A Prospective Study." *American Journal of Obstetrics and Gynecology* 151(3):333–337, 1985.

## Ratio Calculations

### Cephalic Index Ratio

Hadlock FP, Deter RL, Carpenter RJ, Park SK. "Estimating Fetal Age: Effect of Head Shape on BPD." *American Journal of Roentgenology* 137(1):83–85, 1981.

### Head Circumference/Abdominal Circumference Ratio

Campbell S, Thoms A. "Ultrasound Measurement of the Fetal Head to Abdomen Circumference Ratio in the Assessment of Growth Retardation." *British Journal of Obstetrics and Gynaecology* 84(3):165–174, 1977.

### Femur Length/Abdominal Circumference Ratio

Hadlock FP, Deter RL, Harrist RB, Roecker E, Park SK. "A Date-Independent Predictor of Intrauterine Growth Retardation: Femur Length/Abdominal Circumference Ratio." *American Journal of Roentgenology* 141:979–984, 1983.

### Femur Length/Biparietal Diameter Ratio

Hohler CW, Quetel TA. "Comparison of Ultrasound Femur Length and Biparietal Diameter in Late Pregnancy." *American Journal of Obstetrics and Gynecology* 141(7):759–762, 1981.

### Femur Length/Head Circumference Ratio

Hadlock FP, Harrist RB, Shah Y, Park SK. "The Femur Length/Head Circumference Relation in Obstetric Sonography." *Journal of Ultrasound in Medicine* 3(10):439–442, 1984.

### Lateral Ventricle Width/Hemispheric Width Ratio

Johnson ML, Dunne MG, Mack LA, Rashbaum CL. "Evaluation of Fetal Intracranial Anatomy by Static and Real-Time Ultrasound." *Journal of Clinical Ultrasound* 8(4):311–318, 1980.

### Transverse Cerebellar Diameter/Abdominal Circumference Ratio

Meyer WJ, Gauthier DW, Goldenberg B, Santolaya J, Sipos J, Cattledge F. "The Fetal Transverse Cerebellar Diameter/Abdominal Circumference Ratio: A Gestational Age-Independent Method of Assessing Fetal Size." *Journal of Ultrasound in Medicine* 12(7):379–382, 1993.

## Growth Analysis Calculations

### Abdominal Circumference

- Chitty LS, Altman DG. "Charts of Fetal Size: 3. Abdominal Measurements." *British Journal of Obstetrics and Gynaecology* 101(2):125–131, 1994.
- Deter RL, Harrist RB, Hadlock FP, Carpenter RJ. "Fetal Head and Abdominal Circumferences: II. A Critical Reevaluation of the Relationship to Menstrual Age." *Journal Clinical Ultrasound* 10(8):365–372, 1982.
- Hadlock FP, Deter RL, Harrist RB, Park SK. "Estimating Fetal Age: Computer-Assisted Analysis of Multiple Fetal Growth Parameters." *Radiology* 152(2):497–502, 1984.
- Jeanty P, Cousaert E, Cantraine F. "Normal Growth of the Abdominal Perimeter." *American Journal of Perinatology* 1(2):129–135, 1984.
- Merz E, Wellek S. "Normal Fetal Development Profiles - A Model to Obtain Standard Development Graphs for the Head and Abdominal Parameters and the Long Limb Bones." *Ultraschall in der Medizin* 17(4):153–162, 1996.
- Snijders RJ, Nicolaides KH. "Fetal Biometry at 14–40 Weeks' Gestation." *Ultrasound in Obstetrics and Gynecology* 4(1):34–48, 1994.
- Verburg BO, Steegers EA, De Ridder M, Snijders RJ, Smith E, Hofman A, Moll HA, Jaddoe VW, Witteman JC. "New Charts for Ultrasound Dating of Pregnancy and Assessment of Fetal Growth: Longitudinal Data From a Population-based Cohort Study." *Ultrasound in Obstetrics and Gynecology* 31(4):388–396, 2008.
- ASUM 2003:**
- Westerway SC. "Ultrasonic Fetal Measurements for an Australian Population." 2003.  
Adapted from Westerway SC, Davison A, Cowell S. "Ultrasonic Fetal Measurements: New Australian Standards for the New Millennium." *Australian and New Zealand Journal of Obstetrics and Gynaecology* 40(3):297–302, 2000.
- CFEF:**
- Créquat J, Duyme M, Brodaty G. "Biométrie 2000. Tables de croissance fœtale par le Collège Français d'Echographie Fœtale (CFEF) et l'Inserm U155." ("Biometry 2000. Fetal growth charts by the French College of fetal ultrasonography and the Inserm U155.") *Gynécologie Obstétrique and Fertilité* 28(6):435–445, 2000.
- Grumbach (Twin):**
- Grumbach K, Coleman BG, Arger PH, Mintz MC, Gabbe SV, Mennuti MT. "Twin and Singleton Growth Patterns Compared Using US." *Radiology* 158(1):237–241, 1986.
- INTERGROWTH-21st:**
- Papageorghiou AT, Ohuma EO, Altman DG, Todros T, Ismail LC, et al. "International Standards for Fetal Growth Based on Serial Ultrasound Measurements: The Fetal Growth Longitudinal Study of the INTERGROWTH-21st Project." *The Lancet* 384(9946):869–879, 2014.
- JSUM 2003:**
- Japan Society of Ultrasonics in Medicine. "Standardization of Fetometry and Official Announcement of Diagnostic Guidelines." *Journal of Medical Ultrasonics* 30(3):415–440, 2003.

### **Anterior Cerebral Ventricle Diameter (Anterior Horn of Lateral Ventricular Width)**

Snijders RJ, Nicolaides KH. "Fetal Biometry at 14–40 Weeks' Gestation." *Ultrasound in Obstetrics and Gynecology* 4(1):34–48, 1994.

### **Anterior-Posterior Trunk Diameter Multiplied by Transverse Trunk Diameter**

#### **Tokyo:**

Shinozuka N, Okai T, Mizuno M. "Chapter 80. Fetal Measurements." *Obstetrics and Gynecology* Shindan To Iryo Sha Inc., 1989, Vol. 56 Supplement, p. 370–380.

### **Biparietal Diameter**

Hadlock FP, Deter RL, Harrist RB, Park SK. "Estimating Fetal Age: Computer-Assisted Analysis of Multiple Fetal Growth Parameters." *Radiology* 152(2):497–501, 1984.

Hansmann M, Hackelöer B-J, Staudach A. *Ultrasound Diagnosis in Obstetrics and Gynecology*. New York: Springer-Verlag, 1986, English Edition (ISBN 0-387-15384-9); p. 176–177.

Lasser DM, Peisner DB, Vollebergh J, Timor-Tritsch I. "First-trimester Fetal Biometry Using Transvaginal Sonography." *Ultrasound in Obstetrics and Gynecology* 3(2):104–108, 1993.

Merz E, Wellek S. "Normal Fetal Development Profiles - A Model to Obtain Standard Development Graphs for the Head and Abdominal Parameters and the Long Limb Bones." *Ultraschall in der Medizin* 17(4):153–162, 1996.

Snijders RJ, Nicolaides KH. "Fetal Biometry at 14–40 Weeks' Gestation." *Ultrasound in Obstetrics and Gynecology* 4(1):34–48, 1994.

Rempen A. "Biometrie in der Frühgravidität (I. Trimenon) (Biometry in Early Pregnancy [1st Trimester])." *Der Frauenarzt* 32(4):425–430, 1991.

Verburg BO, Steegers EA, De Ridder M, Snijders RJ, Smith E, Hofman A, Moll HA, Jaddoe VW, Witteman JC. "New Charts for Ultrasound Dating of Pregnancy and Assessment of Fetal Growth: Longitudinal Data From a Population-based Cohort Study." *Ultrasound in Obstetrics and Gynecology* 31(4):388–396, 2008.

#### **ASUM 2003:**

Westerway SC. "Ultrasonic Fetal Measurements for an Australian Population." 2003. Adapted from Westerway SC, Davison A, Cowell S. "Ultrasonic Fetal Measurements: New Australian Standards for the New Millennium." *Australian and New Zealand Journal of Obstetrics and Gynaecology* 40(3):297–302, 2000.

#### **CFEF:**

Créquat J, Duyme M, Brodaty G. "Biométrie 2000. Tables de croissance fœtale par le Collège Français d'Echographie Fœtale (CFEF) et l'Inserm U155." ("Biometry 2000. Fetal growth charts by the French College of fetal ultrasonography and the Inserm U155.") *Gynécologie Obstétrique and Fertilité* 28(6):435–445, 2000.

**JSUM 2003:**

Japan Society of Ultrasonics in Medicine. "Standardization of Fetometry and Official Announcement of Diagnostic Guidelines." *Journal of Medical Ultrasonics* 30(3):415–440, 2003.

**Osaka:**

Mineo A. "IUGR Diagnosis and Treatment." *Perinatal Care* 9(5):37–52 (407–422), 1990.

**Chitty (Outer to Inner):**

Chitty LS, Altman DG. "Charts of Fetal Size: 2. Head Measurements." *British Journal of Obstetrics and Gynaecology* 101(1):35–43, 1994.

**Chitty (Outer to Outer):**

Chitty LS, Altman DG. "Charts of Fetal Size: 2. Head Measurements." *British Journal of Obstetrics and Gynaecology* 101(1):35–43, 1994.

**Grumbach (Twin):**

Grumbach K, Coleman BG, Arger PH, Mintz MC, Gabbe SV, Mennuti MT. "Twin and Singleton Growth Patterns Compared Using US." *Radiology* 158(1):237–241, 1986.

**INTERGROWTH-21st:**

Papageorgiou AT, Ohuma EO, Altman DG, Todros T, Ismail LC, et al. "International Standards for Fetal Growth Based on Serial Ultrasound Measurements: The Fetal Growth Longitudinal Study of the INTERGROWTH-21st Project." *The Lancet* 384(9946):869–879, 2014.

**Cerebellum, Transverse Cerebellar Diameter**

Snijders RJ, Nicolaides KH. "Fetal Biometry at 14–40 Weeks' Gestation." *Ultrasound in Obstetrics and Gynecology* 4(1):34–48, 1994.

Verburg BO, Steegers EA, De Ridder M, Snijders RJ, Smith E, Hofman A, Moll HA, Jaddoe VW, Witteman JC. "New Charts for Ultrasound Dating of Pregnancy and Assessment of Fetal Growth: Longitudinal Data From a Population-based Cohort Study." *Ultrasound in Obstetrics and Gynecology* 31(4):388–396, 2008.

**Cerebroplacental Ratio**

Ebbing C, Rasmussen S, Kiserud T. "Middle cerebral artery blood flow velocities and pulsatility index and the cerebroplacental pulsatility ratio: longitudinal reference ranges and terms for serial measurements." *Ultrasound in Obstetrics and Gynecology* 30(3):287–296, 2007.

**Cisterna Magna**

Snijders RJ, Nicolaides KH. "Fetal Biometry at 14–40 Weeks' Gestation." *Ultrasound in Obstetrics and Gynecology* 4(1):34–48, 1994.

**Clavicle Length**

Sherer DM, Sokolovski M, Dalloul M, Khoury-Collado F, Osho JA, Lamarque MD, Abulafia O. "Fetal Clavicle Length throughout Gestation: A Nomogram." *Ultrasound in Obstetrics and Gynecology* 27:306–310, 2006.

**Crown Rump Length**

Hadlock FP, Shah YP, Kanon DJ, Lindsey JV. "Fetal Crown-Rump Length: Reevaluation of Relation to Menstrual Age (5–18 weeks) with High-Resolution Real-Time US." *Radiology* 182(2):501–505, 1992.

Hansmann M, Hackelöer B-J, Staudach A. *Ultrasound Diagnosis in Obstetrics and Gynecology*. New York: Springer-Verlag, 1986, English Edition (ISBN 0-387-15384-9); p. 438.

Pexsters A, Daemen A, Bottomley C, Van Schoubroeck D, De Catte L, et al. "New Crown-rump Length Curve Based on Over 3500 Pregnancies." *Ultrasound in Obstetrics and Gynecology* 35(6):650–655, 2010.

Rempen A. "Biometrie in der Frühgravidität (I. Trimenon) (Biometry in Early Pregnancy [1st Trimester])." *Der Frauenarzt* 32(4):425–430, 1991.

Robinson HP, Fleming JE. "A Critical Evaluation of Sonar 'Crown-rump Length' Measurements." *British Journal of Obstetrics and Gynaecology* 82(9):702–710, 1975.

**ASUM 2003:**

Westerway SC. "Ultrasonic Fetal Measurements for an Australian Population." 2003.  
Adapted from Westerway SC, Davison A, Cowell S. "Ultrasonic Fetal Measurements: New Australian Standards for the New Millennium." *Australian and New Zealand Journal of Obstetrics and Gynaecology* 40(3):297–302, 2000.

**INTERGROWTH-21st:**

Papageorghiou AT, Kennedy SH, Salomon LJ, Ohuma EO, et al. "International Standards for Early Fetal Size and Pregnancy Dating Based on Ultrasound Measurement of Crown-rump Length in the First Trimester of Pregnancy." *Ultrasound in Obstetrics and Gynecology* 44(6):641–648, 2014.

**JSUM 2003:**

Japan Society of Ultrasonics in Medicine. "Standardization of Fetometry and Official Announcement of Diagnostic Guidelines." *Journal of Medical Ultrasonics* 30(3):415–440, 2003.

**Osaka:**

Mineo A. "IUGR Diagnosis and Treatment." *Perinatal Care* 9(5):37–52 (407–422), 1990.

**Tokyo:**

Masuda H, Shinozuka N, Okai T, Mizuno M. "Diagnosis of the Week of Pregnancy and Prognosis." *Perinatal Care* 8:43–50 (719–726).

## Estimated Fetal Weight

Brenner WE, Edelman DA, Hendricks CH. "A Standard of Fetal Growth for the United States of America." *American Journal of Obstetrics and Gynecology* 126(5):555–564, 1976.

Doubilet PT, Benson CB, Nadel AS, Ringer SA. "Improved Birth Weight Table for Neonates Developed from Gestations Dated by Early Ultrasonography." *Journal of Ultrasound in Medicine* 16(4):241–249, 1997.

Hadlock FP, Harrist RB, Martinez-Poyer J. "In Utero Analysis of Fetal Growth: A Sonographic Weight Standard." *Radiology* 181(1):129–133, 1991.

Jeanty P, Cantraine F, Romero R, Cousaert E, Hobbins JC. "A Longitudinal Study of Fetal Weight Growth." *Journal of Ultrasound in Medicine* 3:321–328, 1984.

**Williams (Female, Male):**

Williams RL, Creasy RK, Cunningham GC, Hawes WE, Norris FD, Tashiro M. "Fetal Growth and Perinatal Viability in California." *Obstetrics and Gynecology* 59(5):624–632, 1982.

**Yarkoni (Twin):**

Yarkoni S, Reece EA, Holford T, O'Connor TZ, Hobbins JC. "Estimated Fetal Weight in the Evaluation of Growth in Twin Gestations: A Prospective Longitudinal Study." *Obstetrics and Gynecology* 69(4):636–639, 1987.

**JSUM 2003:**

Japan Society of Ultrasonics in Medicine. "Standardization of Fetometry and Official Announcement of Diagnostic Guidelines." *Journal of Medical Ultrasonics* 30(3):415–440, 2003.

**Osaka:**

Mineo A. "IUGR Diagnosis and Treatment." *Perinatal Care* 9(5):37–52 (407–422), 1990.

**Tokyo:**

Masuda H, Shinozuka N, Okai T, Mizuno M. "Diagnosis of the Week of Pregnancy and Prognosis." *Perinatal Care* 8:43–50 (719–726).

**INTERGROWTH-21st:**

Stirnemann J, Villar J, Salomon LJ, et al. "International Estimated Fetal Weight Standards of the INTERGROWTH-21st Project." *Ultrasound in Obstetrics and Gynecology* 49(4):478–486, 2017.

## Femur Length

- Chitty LS, Altman DG. "Charts of Fetal Size: 4. Femur Length." *British Journal of Obstetrics and Gynaecology* 101(2):132–135, 1994.
- Hadlock FP, Deter RL, Harrist RB, Park SK. "Estimating Fetal Age: Computer-Assisted Analysis of Multiple Fetal Growth Parameters." *Radiology* 152(2):497–501, 1984.
- Hansmann M, Hackelöer B-J, Staudach A. *Ultrasound Diagnosis in Obstetrics and Gynecology*. New York: Springer-Verlag, 1986, English Edition (ISBN 0-387-15384-9); p. 182.
- Jeanty P, Cousaert E, Cantraine F, Hobbins JC, Tack B, Struyven J. "A Longitudinal Study of Fetal Limb Growth." *American Journal of Perinatology* 1(2):136–144, 1984.
- Merz E, Wellek S. "Normal Fetal Development Profiles - A Model to Obtain Standard Development Graphs for the Head and Abdominal Parameters and the Long Limb Bones." *Ultraschall in der Medizin* 17(4):153–162, 1996.
- Snijders RJ, Nicolaides KH. "Fetal Biometry at 14–40 Weeks' Gestation." *Ultrasound in Obstetrics and Gynecology* 4(1):34–48, 1994.
- Verburg BO, Steegers EA, De Ridder M, Snijders RJ, Smith E, Hofman A, Moll HA, Jaddoe VW, Witteman JC. "New Charts for Ultrasound Dating of Pregnancy and Assessment of Fetal Growth: Longitudinal Data From a Population-based Cohort Study." *Ultrasound in Obstetrics and Gynecology* 31(4):388–396, 2008.
- Warda AH, Deter RL, Rossavik IK, Carpenter RJ, Hadlock FP. "Fetal Femur Length: A Critical Reevaluation of Relationship to Menstrual Age." *Obstetrics and Gynecology* 66(1):69–75, 1985.
- ASUM 2003:**
- Westerway SC. "Ultrasonic Fetal Measurements for an Australian Population." 2003.  
Adapted from Westerway SC, Davison A, Cowell S. "Ultrasonic Fetal Measurements: New Australian Standards for the New Millennium." *Australian and New Zealand Journal of Obstetrics and Gynaecology* 40(3):297–302, 2000.
- CFEF:**
- Créquat J, Duyme M, Brodaty G. "Biométrie 2000. Tables de croissance fœtale par le Collège Français d'Echographie Fœtale (CFEF) et l'Inserm U155." ("Biometry 2000. Fetal growth charts by the French College of fetal ultrasonography and the Inserm U155.") *Gynécologie Obstétrique and Fertilité* 28(6):435–445, 2000.
- INTERGROWTH-21st:**
- Papageorgiou AT, Ohuma EO, Altman DG, Todros T, Ismail LC, et al. "International Standards for Fetal Growth Based on Serial Ultrasound Measurements: The Fetal Growth Longitudinal Study of the INTERGROWTH-21st Project." *The Lancet* 384(9946):869–879, 2014.
- JSUM 2003:**
- Japan Society of Ultrasonics in Medicine. "Standardization of Fetometry and Official Announcement of Diagnostic Guidelines." *Journal of Medical Ultrasonics* 30(3):415–440, 2003.
- Osaka:**
- Mineo A. "IUGR Diagnosis and Treatment." *Perinatal Care* 9(5):37–52 (407–422), 1990.
- Tokyo:**
- Shinozuka N, Okai T, Mizuno M. "Chapter 80. Fetal Measurements." *Obstetrics and Gynecology Shindan To Iryo Sha Inc.*, 1989, Vol. 56 Supplement, p. 370–380.

## Fetal Trunk Area

- Osaka:**
- Mineo A. "IUGR Diagnosis and Treatment." *Perinatal Care* 9(5):37–52 (407–422), 1990.

## Foot Length

- Chitty LS, Altman DG. "Charts of Fetal Size: Limb Bones." *British Journal of Obstetrics and Gynaecology* 109(8):919–929, 2002.
- Mercer BM, Sklar S, Shariatmadar A, Gillieson MS, D'Alton ME. "Fetal Foot Length as a Predictor of Gestational Age." *American Journal of Obstetrics and Gynecology* 156(2):350–355, 1987.

## Gestational Sac Diameter

- Hellman LM, Kobayashi M, Fillisti L, Lavenhar M. "Growth and Development of the Human Fetus Prior to the Twentieth Week of Gestation." *American Journal of Obstetrics and Gynecology* 103:789–800, 1969.
- Rempen A. "Biometrie in der Frühgravidität (I. Trimenon) (Biometry in Early Pregnancy [1st Trimester])." *Der Frauenarzt* 32(4):425–430, 1991.

### Tokyo:

- Masuda H, Shinozuka N, Okai T, Mizuno M. "Diagnosis of the Week of Pregnancy and Prognosis." *Perinatal Care* 8:43–50 (719–726).

## Head Circumference

- Chitty LS, Altman DG. "Charts of Fetal Size: 2. Head Measurements." *British Journal of Obstetrics and Gynaecology* 101(1):35–43, 1994.
- Deter RL, Harrist RB, Hadlock FP, Carpenter RJ. "Fetal Head and Abdominal Circumferences: II. A Critical Reevaluation of the Relationship to Menstrual Age." *Journal Clinical Ultrasound* 10(8):365–372, 1982.
- Hadlock FP, Deter RL, Harrist RB, Park SK. "Estimating Fetal Age: Computer-Assisted Analysis of Multiple Fetal Growth Parameters." *Radiology* 152(2):497–502, 1984.
- Hansmann M, Hackelöer B-J, Staudach A. *Ultrasound Diagnosis in Obstetrics and Gynecology*. New York: Springer-Verlag, 1986, English Edition (ISBN 0-387-15384-9); p. 176.
- Merz E, Wellek S. "Normal Fetal Development Profiles - A Model to Obtain Standard Development Graphs for the Head and Abdominal Parameters and the Long Limb Bones." *Ultraschall in der Medizin* 17(4):153–162, 1996.
- Snijders RJ, Nicolaides KH. "Fetal Biometry at 14–40 Weeks' Gestation." *Ultrasound in Obstetrics and Gynecology* 4(1):34–48, 1994.
- Verburg BO, Steegers EA, De Ridder M, Snijders RJ, Smith E, Hofman A, Moll HA, Jaddoe VW, Witteman JC. "New Charts for Ultrasound Dating of Pregnancy and Assessment of Fetal Growth: Longitudinal Data From a Population-based Cohort Study." *Ultrasound in Obstetrics and Gynecology* 31(4):388–396, 2008.

### ASUM 2003:

- Westerway SC. "Ultrasonic Fetal Measurements for an Australian Population." 2003.  
Adapted from Westerway SC, Davison A, Cowell S. "Ultrasonic Fetal Measurements: New Australian Standards for the New Millennium." *Australian and New Zealand Journal of Obstetrics and Gynaecology* 40(3):297–302, 2000.

### CFEF:

- Créquat J, Duyme M, Brodaty G. "Biométrie 2000. Tables de Croissance Fœtale par le Collège Français d'Echographie Fœtale (CFEF) et l'Inserm U155." ("Biometry 2000. Fetal Growth Charts by the French College of Fetal Ultrasonography and the Inserm U155.") *Gynécologie Obstétrique and Fertilité* 28(6):435–445, 2000.

### INTERGROWTH-21st:

- Papageorghiou AT, Ohuma EO, Altman DG, Todros T, Ismail LC, et al. "International Standards for Fetal Growth Based on Serial Ultrasound Measurements: The Fetal Growth Longitudinal Study of the INTERGROWTH-21st Project." *The Lancet* 384(9946):869–879, 2014.

## Head Circumference to Abdominal Circumference Ratio

Campbell S, Thoms A. "Ultrasound Measurement of the Fetal Head to Abdomen Circumference Ratio in the Assessment of Growth Retardation." *British Journal of Obstetrics and Gynaecology* 84(3):165–174, 1977.

## Humerus Length

Chitty LS, Altman DG. "Charts of Fetal Size: Limb Bones." *British Journal of Obstetrics and Gynaecology* 109(8):919–929, 2002.

Hansmann M, Hackelöer B-J, Staudach A. *Ultrasound Diagnosis in Obstetrics and Gynecology*. New York: Springer-Verlag, 1986, English Edition (ISBN 0-387-15384-9); p. 183.

Jeanty P, Cousaert E, Cantraine F, Hobbins JC, Tack B, Struyven J. "A Longitudinal Study of Fetal Limb Growth." *American Journal of Perinatology* 1(2):136–144, 1984.

Merz E, Wellek S. "Normal Fetal Development Profiles - A Model to Obtain Standard Development Graphs for the Head and Abdominal Parameters and the Long Limb Bones." *Ultraschall in der Medizin* 17(4):153–162, 1996.

### ASUM 2003:

Westerway SC. "Ultrasonic Fetal Measurements for an Australian Population." 2003. Adapted from Westerway SC, Davison A, Cowell S. "Ultrasonic Fetal Measurements: New Australian Standards for the New Millennium." *Australian and New Zealand Journal of Obstetrics and Gynaecology* 40(3):297–302, 2000.

### Osaka:

Mineo A. "IUGR Diagnosis and Treatment." *Perinatal Care* 9(5):37–52 (407–422), 1990.

## Kidney Anterior-Posterior Diameter, Kidney Length

Bertagnoli L, Lalatta F, Gallicchio R, Fantuzzi M, Rusca M, Zorzoli A, Deter RL. "Quantitative Characterization of the Growth of the Fetal Kidney." *Journal of Clinical Ultrasound* 11(7):349–356, 1983.

Hansmann M, Hackelöer B-J, Staudach A. *Ultrasound Diagnosis in Obstetrics and Gynecology*. New York: Springer-Verlag, 1986, English Edition (ISBN 0-387-15384-9); p. 180.

## Interval Growth Rate

Nazarian LN, Halpern EJ, Kurtz AB, Hauck WW, Needleman L. "Normal Interval Fetal Growth Rates Based on Obstetrical Ultrasonographic Measurements." *Journal of Ultrasound in Medicine* 14(11):829–836, 1995.

## Mean Abdominal Diameter

Kurmanavicius J, Huch A, et al. "Standard – Tabellen und Kurven für Ultraschall- / Dopplersonografie." UniversitätsSpital Zürich, Dept. Frauenheilkunde Klinik und Poliklinik für Geburtshilfe; 1997.

### Mean Sac Diameter

Hellman LM, Kobayashi M, Fillisti L, Lavenhar M. "Growth and Development of the Human Fetus Prior to the Twentieth Week of Gestation." *American Journal of Obstetrics and Gynecology* 103:789–800, 1969.

Rempen A. "Biometrie in der Frühgravidität (I. Trimenon) (Biometry in Early Pregnancy [1st Trimester])." *Der Frauenarzt* 32(4):425–430, 1991.

### Middle Cerebral Artery: Pulsatility Index, Resistive Index

#### JSUM 2003:

Japan Society of Ultrasonics in Medicine. "Standardization of Fetometry and Official Announcement of Diagnostic Guidelines." *Journal of Medical Ultrasonics* 30(3):415–440, 2003.

Ebbing C, Rasmussen S, Kiserud T. "Middle cerebral artery blood flow velocities and pulsatility index and the cerebroplacental pulsatility ratio: longitudinal reference ranges and terms for serial measurements." *Ultrasound in Obstetrics and Gynecology* 30(3):287–296, 2007.

### Occipital Frontal Diameter

Chitty LS, Altman DG. "Charts of Fetal Size: 2. Head Measurements." *British Journal of Obstetrics and Gynaecology* 101(1):35–43, 1994.

Hansmann M, Hackelöer B-J, Staudach A. *Ultrasound Diagnosis in Obstetrics and Gynecology*. New York: Springer-Verlag, 1986, English Edition (ISBN 0-387-15384-9); p. 176–177.

Snijders RJ, Nicolaides KH. "Fetal Biometry at 14–40 Weeks' Gestation." *Ultrasound in Obstetrics and Gynecology* 4(1):34–48, 1994.

#### ASUM 2003:

Westerway SC. "Ultrasonic Fetal Measurements for an Australian Population." 2003. Adapted from Westerway SC, Davison A, Cowell S. "Ultrasonic Fetal Measurements: New Australian Standards for the New Millennium." *Australian and New Zealand Journal of Obstetrics and Gynaecology* 40(3):297–302, 2000.

#### INTERGROWTH-21st:

Papageorghiou AT, Ohuma EO, Altman DG, Todros T, Ismail LC, et al. "International Standards for Fetal Growth Based on Serial Ultrasound Measurements: The Fetal Growth Longitudinal Study of the INTERGROWTH-21st Project." *The Lancet* 384(9946):869–879, 2014.

### Posterior Cerebral Ventricle Diameter (Posterior Horn of Lateral Ventricular Width)

Snijders RJ, Nicolaides KH. "Fetal Biometry at 14–40 Weeks' Gestation." *Ultrasound in Obstetrics and Gynecology* 4(1):34–48, 1994.

### Transverse Abdominal Diameter

#### CFEF:

Créquat J, Duyme M, Brodaty G. "Biométrie 2000. Tables de croissance fœtale par le Collège Français d'Echographie Fœtale (CFEF) et l'Inserm U155." ("Biometry 2000. Fetal growth charts by the French College of fetal ultrasonography and the Inserm U155.") *Gynécologie Obstétrique and Fertilité* 28(6):435–445, 2000.

### Thoracic Circumference

Chitkara U, Rosenberg J, Chervenak FA, Berkowitz GS, Levine R, Fagerstrom RM, Walker B, Berkowitz RL. "Prenatal Sonographic Assessment of the Fetal Thorax: Normal Values." *American Journal of Obstetrics and Gynecology* 156(5):1069–1074, 1987.

## Tibia Length

- Chitty LS, Altman DG. "Charts of Fetal Size: Limb Bones." *British Journal of Obstetrics and Gynaecology* 109(8):919–929, 2002.
- Hansmann M, Hackelöer B-J, Staudach A. *Ultrasound Diagnosis in Obstetrics and Gynecology*. New York: Springer-Verlag, 1986, English Edition (ISBN 0-387-15384-9); p. 182.
- Jeanty P, Coussaert E, Cantraine F, Hobbins JC, Tack B, Struyven J. "A Longitudinal Study of Fetal Limb Growth." *American Journal of Perinatology* 1(2):136–144, 1984.
- Merz E, Wellek S. "Normal Fetal Development Profiles - A Model to Obtain Standard Development Graphs for the Head and Abdominal Parameters and the Long Limb Bones." *Ultraschall in der Medizin* 17(4):153–162, 1996.

## Ulna Length

- Chitty LS, Altman DG. "Charts of Fetal Size: Limb Bones." *British Journal of Obstetrics and Gynaecology* 109(8):919–929, 2002.
- Hansmann M, Hackelöer B-J, Staudach A. *Ultrasound Diagnosis in Obstetrics and Gynecology*. New York: Springer-Verlag, 1986, English Edition (ISBN 0-387-15384-9); p. 183.
- Jeanty P, Coussaert E, Cantraine F, Hobbins JC, Tack B, Struyven J. "A Longitudinal Study of Fetal Limb Growth." *American Journal of Perinatology* 1(2):136–144, 1984.
- Merz E, Wellek S. "Normal Fetal Development Profiles - A Model to Obtain Standard Development Graphs for the Head and Abdominal Parameters and the Long Limb Bones." *Ultraschall in der Medizin* 17(4):153–162, 1996.

## Umbilical Artery: Pulsatility Index, Resistive Index

### JSUM 2003:

- Japan Society of Ultrasonics in Medicine. "Standardization of Fetometry and Official Announcement of Diagnostic Guidelines." *Journal of Medical Ultrasonics* 30(3):415–440, 2003.

## Additional Obstetric References

### Abdominal Circumference Calculated from Anterior-Posterior Abdominal Diameter and Transverse Abdominal Diameter

- Salomon LJ, Alfievic Z, Berghella V, Bilardo C, Hernandez-Andrade E, Johnsen SL, et al. on behalf of the International Society of Ultrasound in Obstetrics and Gynecology (ISUOG) Clinical Standards Committee. "Practice Guidelines for Performance of the Routine Mid-trimester Fetal Ultrasound Scan." *Ultrasound in Obstetrics and Gynecology*, 2010.

### Head Circumference Calculated from Occipital-Frontal Diameter and Biparietal Diameter

- Salomon LJ, Alfievic Z, Berghella V, Bilardo C, Hernandez-Andrade E, Johnsen SL, et al. on behalf of the International Society of Ultrasound in Obstetrics and Gynecology (ISUOG) Clinical Standards Committee. "Practice Guidelines for Performance of the Routine Mid-trimester Fetal Ultrasound Scan." *Ultrasound in Obstetrics and Gynecology*, 2010.

## Biophysical Profile

- Manning FA. "Dynamic Ultrasound-Based Fetal Assessment: The Fetal Biophysical Profile Score." *Clinical Obstetrics and Gynecology* 38(1):26–44, 1995.
- Vintzileos AM, Campbell WA, Ingardia CJ, Nochimson DJ. "The Fetal Biophysical Profile and Its Predictive Value." *Obstetrics and Gynecology* 62(3):271–278, 1983.

## Pediatric Hip Clinical References

Graf R. "Sonographic Diagnosis of Hip Dysplasia and Hip Dislocation." Revised from reprint: Schuler P, Graf R. "Sonographie in der Orthopädie" in Braun - Günther - Schwerk. *Ultraschalldiagnostik*, 4. Erg. Lfg 7, 1986.

## Transcranial Imaging Clinical References

American College of Radiology (ACR), Society for Pediatric Radiology (SPR), Society of Radiologists in Ultrasound (SRU). "AIUM Practice Guideline for the Performance of a Transcranial Doppler Ultrasound Examination for Adults and Children." *Journal of Ultrasound in Medicine* 31(9):1489–1500, 2012.

American College of Radiology. *ACR–AIUM–SPR–SRU Practice Parameter for the Performance of Transcranial Doppler Ultrasound*, American College of Radiology Resolution 39, Amended 2014.

Lindegaard KF, Nornes H, Bakke SJ, et al. "Cerebral Vasospasm after Subarachnoid Haemorrhage Investigated by Means of Transcranial Doppler Ultrasound." *Acta Neurochirurgica Supplementum* 42:81–84, 1988.

Lindegaard KF, Nornes H, Bakke SJ, et al. "Cerebral Vasospasm Diagnosis by Means of Angiography and Blood Velocity Measurements." *Acta Neurochirurgica* 100(1-2):12–24, 1989.

Naqvi J, Yap KH, Ahmad G, Ghosh J. "Transcranial Doppler Ultrasound: A Review of the Physical Principles and Major Applications in Critical Care." *International Journal of Vascular Medicine* 2013 (629378), 2013.

Nichols, FT, Jones AM, Adams RJ. "Stroke Prevention in Sickle Cell Disease (STOP) Study Guidelines for Transcranial Doppler Testing." *Journal of Neuroimaging* 11(4):354–362, 2001.

Society for Vascular Ultrasound. *Transcranial Doppler in Pediatric Patients with Sickle Cell Anemia: (Non-Imaging)*. Maryland: Society for Vascular Ultrasound, 2012.

## Ultrasound-Derived Fat Fraction Clinical References

Han A, Andre MP, Erdman JW, Loomba R, Sirlin CB, O'Brien WD. "Repeatability and Reproducibility of a Clinically Based QUS Phantom Study and Methodologies." *IEEE Transactions on Ultrasonics, Ferroelectrics, and Frequency Control* 64(1):218–231, 2017.

Han A, Labyed Y, Andre MP, Erdman JW, Loomba R, Sirlin CB, O'Brien WD. "Inter-sonographer Reproducibility of Quantitative Ultrasound Outcomes and Shear Wave Speed Measured in the Right Lobe of the Liver in Adults with Known or Suspected Nonalcoholic Fatty Liver Disease." *European Radiology* 28(12):4992–5000, 2018.

Han A, Zhang YN, Boehringer AS, Montes V, Andre MP, Erdman JW Jr, Loomba R, Valasek MA, Sirlin CB, O'Brien WD Jr. "Assessment of Hepatic Steatosis in Nonalcoholic Fatty Liver Disease by Using Quantitative US." *Radiology* 295(1):106–113, 2020.

Lin SC, Heba E, Wolfson T, Ang B, Gamst A, Han A, Erdman JW, O'Brien WD, Andre MP, Sirlin CB, Loomba R. "Noninvasive Diagnosis of Nonalcoholic Fatty Liver Disease and Quantification of Liver Fat using a New Quantitative Ultrasound Technique." *Clinical Gastroenterology and Hepatology* 13(7):1337–1345, 2015.

Paige JS, Bernstein GS, Heba E, Costa EAC, Ferreira M, Wolfson T, Gamst AC, Valasek MA, Lin GY, Han A, et al. "A Pilot Comparative Study of Quantitative Ultrasound, Conventional Ultrasound, and MRI for Predicting Histology-Determined Steatosis Grade in Adult Nonalcoholic Fatty Liver Disease." *American Journal of Roentgenology* 208(5):W168–W177, 2017.

Tang A, Tan J, Sun M, Hamilton G, Bydder M, Wolfson T, Gamst AC, Middleton M, Brunt EM, Loomba R, Lavine JE, Schwimmer JB, Sirlin CB. "Nonalcoholic Fatty Liver Disease: MR Imaging of Liver Proton Density Fat Fraction to Assess Hepatic Steatosis." *Radiology* 267(2):422–31, 2013.

Yokoo T, Bydder M, Hamilton G, Middleton MS, Gamst AC, Wolfson T, Hassanein T, Patton HM, Lavine JE, Schwimmer JB, Sirlin CB. "Nonalcoholic Fatty Liver Disease: Diagnostic and Fat-grading Accuracy of Low-flip-angle Multiecho Gradient-recalled-echo MR Imaging at 1.5 T." *Radiology* 251(1):67–76, 2009.

## Stress Echo Clinical References

Schiller NB, Shah PM, Crawford M, et al. "Recommendations for Quantification of the Left Ventricle by Two-Dimensional Echocardiography." *Journal of the American Society of Echocardiography* 2(5):364, 1989.

## Pulsatility Index Calculation References

Burns PN. "The Physical Principles of Doppler and Spectral Analysis." *Journal of Clinical Ultrasound* 15(9):567–590, 1987.

Gosling RG, Dunbar G, King DH, et al. "The Quantitative Analysis of Occlusive Peripheral Arterial Disease by a Non-intrusive Ultrasonic Technique." *Angiology* 22(1):52–55, 1971.

## Virtual Touch Clinical References

Barr RG, Engel A, Kim S, et al. "Improved Breast 2D SWE Algorithm to Eliminate False-Negative Cases." *Investigative Radiology* 58(10):703–709, 2023.

Deng Y, Rouze NC, Palmeri ML, Nightingale KR. "Ultrasonic Shear Wave Elasticity Imaging Sequencing and Data Processing Using a Verasonics Research Scanner." *IEEE Transactions on Ultrasonics, Ferroelectrics, and Frequency Control* 64(1):164–176, 2017.

Dillman JR, Trout AT. "Multisample Ultrasound Point Shear Wave Elastography of the Liver: Repeatability and Agreement With Conventional Point Shear Wave Elastography." *Journal of Ultrasound in Medicine* 42(12):2749–2756, 2023.

Gilligan LA, Trout AT, Bennett P, et al. "Repeatability and Agreement of Shear Wave Speed Measurements in Phantoms and Human Livers Across 6 Ultrasound 2-Dimensional Shear Wave Elastography Systems." *Investigative Radiology* 55(4):191–199, 2020.

Rouze NC, Deng Y, Trutna CA, et al. "Characterization of Viscoelastic Materials Using Group Shear Wave Speeds." *IEEE Transactions on Ultrasonics, Ferroelectrics, and Frequency Control* 65(5):780–794, 2018.

## Vascular Clinical References

### Carotid Intima-Media Thickness

Riley WA, Barnes RW, Applegate WB, et al. "Reproducibility of Noninvasive Ultrasonic Measurement of Carotid Atherosclerosis: The Asymptomatic Carotid Artery Plaque Study." *Stroke* 23(8):1062–1068, 1992.

Umemura S, Arima H, Arima S, et al. "The Japanese Society of Hypertension Guidelines for the Management of Hypertension." *Hypertension Research* 42(9):1235–1481, 2019.

## Volume Clinical References

- American Institute of Ultrasound in Medicine, American College of Radiology, Society for Pediatric Radiology, et al. "AIUM Practice Guideline for the Performance of Scrotal Ultrasound Examinations." *Journal of Ultrasound in Medicine* 34(8):1–5, 2015.
- Amole AO, Kuranga SA, Oyejola BA. "Sonographic Assessment of Postvoid Residual Urine Volumes in Patients with Benign Prostatic Hyperplasia." *Journal of the National Medical Association* 96(2):234–239, 2004.
- Bakker J, Olree M, Kaatee R, et al. "Renal Volume Measurements: Accuracy and Repeatability of US Compared with that of MR Imaging." *Radiology* 211(3):623–628, 1999.
- Dicuio M, Pomara G, Menchini Fabris F, et al. "Measurements of Urinary Bladder Volume: Comparison of Five Ultrasound Calculation Methods in Volunteers." *Archivio Italiano di Urologia e Andrologia* 77(1):60–62, 2005.
- Dodds WJ, Groh WJ, Darweesh RM, et al. "Sonographic Measurement of Gallbladder Volume." *American Journal of Roentgenology* 145(5):1009–1011, 1985.
- Eri LM, Thomassen H, Brennhovd B, et al. "Accuracy and Repeatability of Prostate Volume Measurements by Transrectal Ultrasound." *Prostate Cancer and Prostatic Diseases* 5(4):273–278, 2002.
- Moorthy HK, Venugopal P. "Measurement of Renal Dimensions in Vivo. A Critical Appraisal." *Indian Journal of Urology* 27(2):169–175, 2011.
- Nwosu CR, Khan KS, Chien PF, et al. "Is Real-time Ultrasonic Bladder Volume Estimation Reliable and Valid? A Systematic Overview." *Scandinavian Journal of Urology and Nephrology* 32(5):325–330, 1998.
- Paltiel HJ, Diamond DA, Di Canzio J, et al. "Testicular Volume: Comparison of Orchidometer and US Measurements in Dogs." *Radiology* 222(1):114–119, 2002.
- Pilatz A, Rusz A, Wagenlehner F, et al. "Reference Values for Testicular Volume, Epididymal Head Size and Peak Systolic Velocity of the Testicular Artery in Adult Males Measured by Ultrasonography." *Ultraschall in der Medizin* 34(4):349–354, 2013.
- Prassopoulos P, Daskalogiannaki M, Raissaki M, et al. "Determination of Normal Splenic Volume on Computed Tomography in Relation to Age, Gender and Body Habitus." *European Radiology* 7(2):246–248, 1997.
- Shabana W, Peeters E, De Maeseneer M. "Measuring Thyroid Gland Volume: Should We Change the Correction Factor?" *American Journal of Roentgenology* 186(1):234–236, 2006.
- Shabana W, Peeters E, Verbeek P, et al. "Reducing Inter-observer Variation in Thyroid Volume Calculation Using a New Formula and Technique." *European Journal of Ultrasound* 16(3):207–210, 2003.
- Yetter, EM, Acosta KB, Olson MC, et al. "Estimating Splenic Volume: Sonographic Measurements Correlated with Helical CT Determination." *American Journal of Roentgenology* 181(6):1615–1620, 2003.

## Thyroid

- Brunn J, Block U, Ruf G, et al. "Volumetric Analysis of Thyroid Lobes by Real-time Ultrasound (Author's translation)." *Deutsche Medizinische Wochenschrift* 106(41):1338–1340, 1981.



