


## NARROW BAND IMAGING (NBI)

A New Wave of Diagnostic Possibilities.



# LIGHT ABSORPTION MAKES ALL THE DIFFERENCE

EVIS EXERA III offers improved NBI and advances the art of visualisation. Olympus Narrow Band Imaging (NBI) has set a new standard for endoscopy. This brochure provides an insight into the innovative technology of NBI and demonstrates how it works to optimise endoscopy imaging. Several clinical studies are presented that analyse the overwhelming potential for using NBI in the early detection of cancer.

## NBI Achieve More with NBI

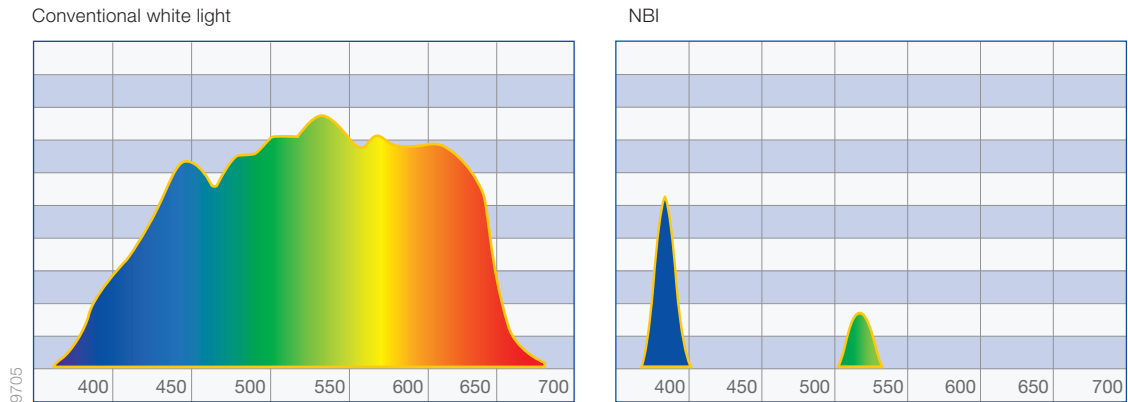
NBI is a powerful optical image enhancement technology, which improves the visibility of blood vessels and mucosal structures.

### How does NBI work?

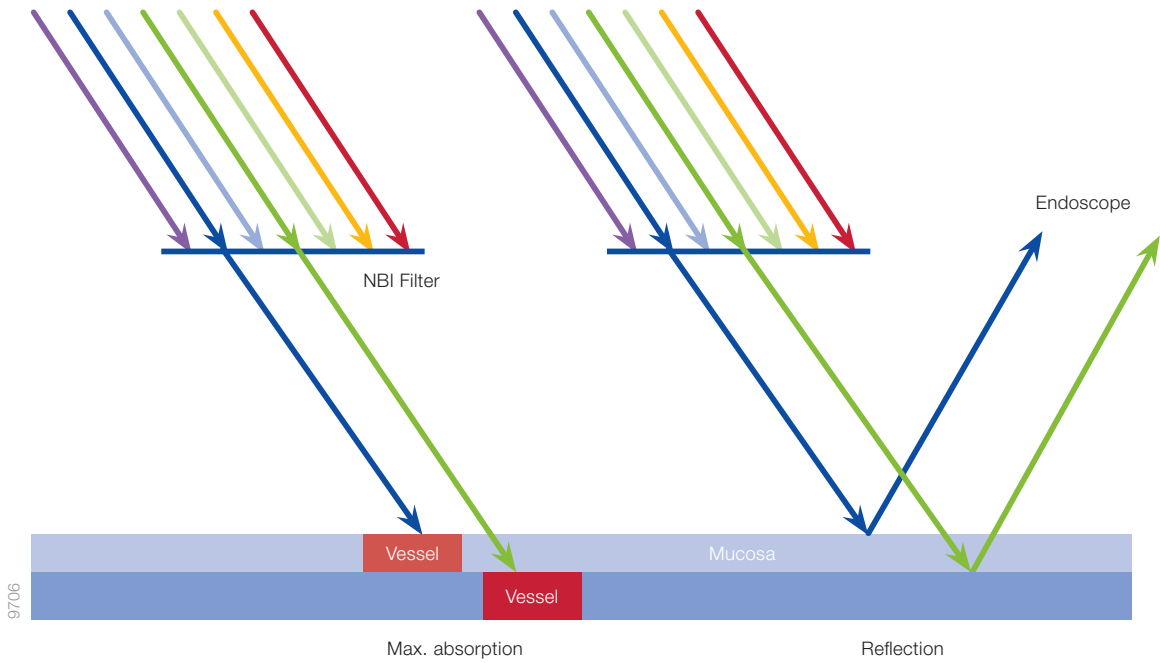
NBI utilises the properties of light. The visible spectrum is the portion of the electromagnetic spectrum that can be seen by the human eye as colour. This correlates to wavelengths of 390nm to 700nm. Once an object is illuminated, some of the wavelengths are absorbed and other wavelengths are reflected from the surface. The reflected wavelengths are detected by the human eye as colour. White light usually comprises of the full spectrum of visible light. So when using white light endoscopy (WLE), a large number of wavelengths are emitted from the endoscope.

In contrast, when NBI is used, white light is passed through a filter, which removes the majority of wavelengths of visible light and only allows light through that is strongly absorbed by haemoglobin. Therefore, narrow band imaging only consists of two wavelengths; blue light (415 nm) and green light (540 nm).

NBI light is absorbed by the haemoglobin in blood vessels but reflected by the surrounding mucosa. Maximum contrast is created between the vessels and the surrounding mucosa which is beneficial when viewing subtle changes. The shorter wavelength light, blue light of 415nm, only penetrates the superficial layers of the mucosa and is absorbed by the capillary vessels on the surface. These capillaries are observed in a dark brown colour and can assist in the detection of tumours, which are often highly vascularised. The longer wavelength light 540 nm, green light, penetrates deeper and is absorbed by blood vessels located deeper within the mucosal layer and will appear in a cyan colour. It is particularly helpful to display the deeper vasculature of suspect lesions. In addition, the visualisation of the capillary system is less blurred or distorted, which can occur from the scattering of wavelengths in white light endoscopy.



In contrast to white light, NBI light is composed of only two specific bands of light.



Absorption of narrow band light by capillaries on the mucosal surface (blue) and veins in the submucosa (green).

### EVIS EXERA III with NBI – More Power for Accurate Diagnosis

The latest EVIS EXERA III video endoscopy system from Olympus features improved NBI technology. Advances in the system have allowed physicians to achieve the best possible endoscopy imaging. A brighter light source, combined with Olympus most advanced video processor and a more sensitive CCD in endoscope, all contribute to improved imaging. The EVIS EXERA III system provides up to twice-the-viewable distance when using NBI, as compared to previous generation, EVIS EXERA II.

CREATE HIGH-QUALITY IMAGES

EVIS EXERA III has a large number of innovative functions that all contribute to advanced imaging for improved diagnosis. The following chapter will demonstrate how to get the most from the system's latest technologies.

Begin with Good Patient Preparation

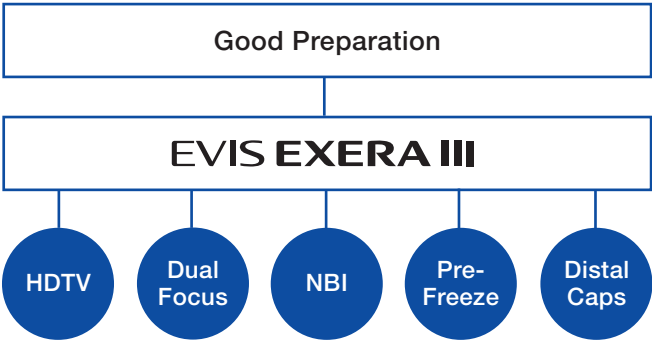
Good bowel preparation is mandatory when it comes to colonoscopy. If the bowel is poorly prepared, optical diagnosis are difficult to make.

Flushing Pumps

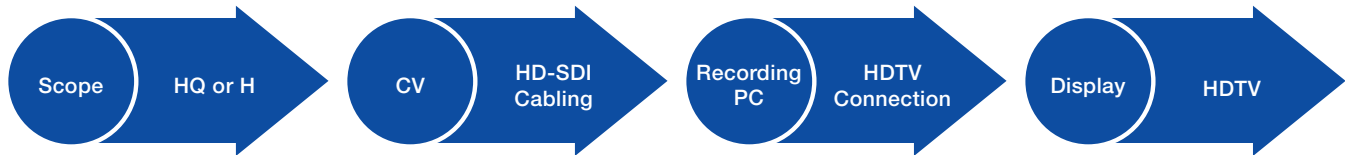
Flushing pumps can easily be attached to the endoscope in order to irrigate via the instrument channel or the auxiliary water channel (water jet). This is very helpful to efficiently wash away any debris or remaining organic material during endoscopic examinations. Furthermore the use of flushing pumps can also assist with the identification of sources of bleeding during a procedure. Additional applications of the flushing pump include “underwater” endoscopy, where the flushing pump is used to fill the colon with water and can enhance the clarity of structures. Lastly, it can also assist during endoscopic ultrasound procedures.

Technologies for Better Vision – and the Best Image Composition

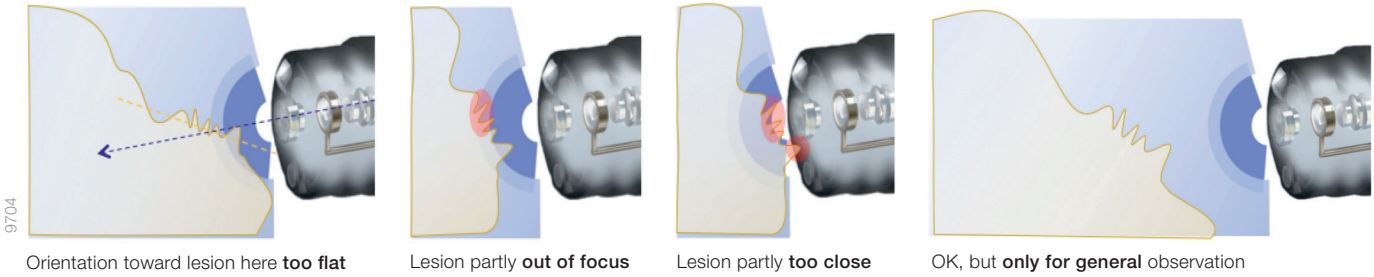
The cutting-edge EVIS EXERA III endoscopy system provides you with versatile technologies to enhance image quality. These include: HDTV, optical magnification with Dual Focus, NBI and Pre-Freeze to achieve sharp endoscopic images. Olympus EndoTherapy product range includes a range of distal caps which can assist in stabilising the distal end of the endoscope during procedures.



The higher the image resolution, the greater the opportunity to detect lesions at an early stage. The EVIS EXERA III platform combined with HQ endoscopes and latest Monitor OEV-262H offers the most advanced imaging which helps you see significantly more. At Olympus, it is referred to as the HDTV chain.



To get the best out of your images, verify that none of the components breaks the HDTV chain.

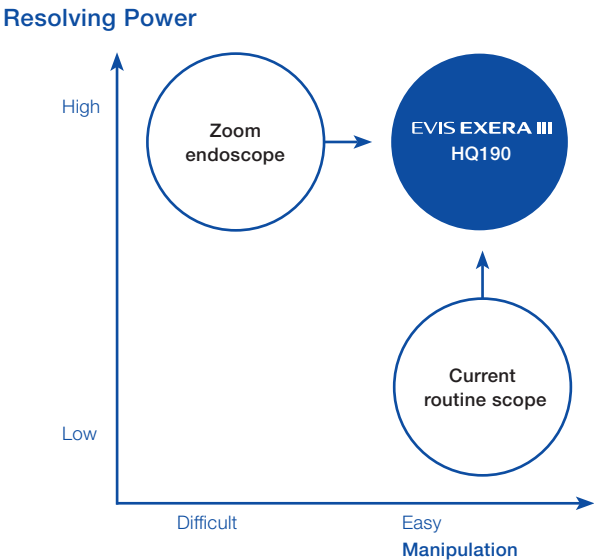


In “near mode,” ensure that the lesion is at the right distance and orientation. Otherwise, the still image may not be sufficient to confirm your diagnosis.



Dual Focus (DF) is an innovative two-stage optical technology, which is available in the HQ range of endoscopes. It was developed, with the zoom scope in mind, focusing on two key factors: resolving power and scope handling. The HQ endoscope range is comparable with previous zoom endoscopes, in terms of resolving power, however they surpass zoom endoscopes in terms of handling for the physician. DF allows you to switch between two focus settings: “normal mode” and “near mode” by simply pressing a scope button.

Zoom endoscopes offer 7–100 mm depth of field in “wide mode” and 2–3 mm in “near mode” (“tele mode”). This results in a viewing gap of 3–7 mm which causes a blind area and furthermore the small range of “tele mode” only provides a limited field of view. In contrast to this, the normal and near mode of the HQ endoscopes conveniently overlap each other. The “normal mode” suits normal observation at a distance of 5–100 mm with a 170° field of view, while the “near mode” allows close observation of the finest mucosal surfaces at a distance of 2–6 mm. If you switch to the “near mode”, the field of view will remain almost the same (160°). This not only saves valuable time to attain the desired view, but also facilitates staying in focus and achieving a good diagnostic image.

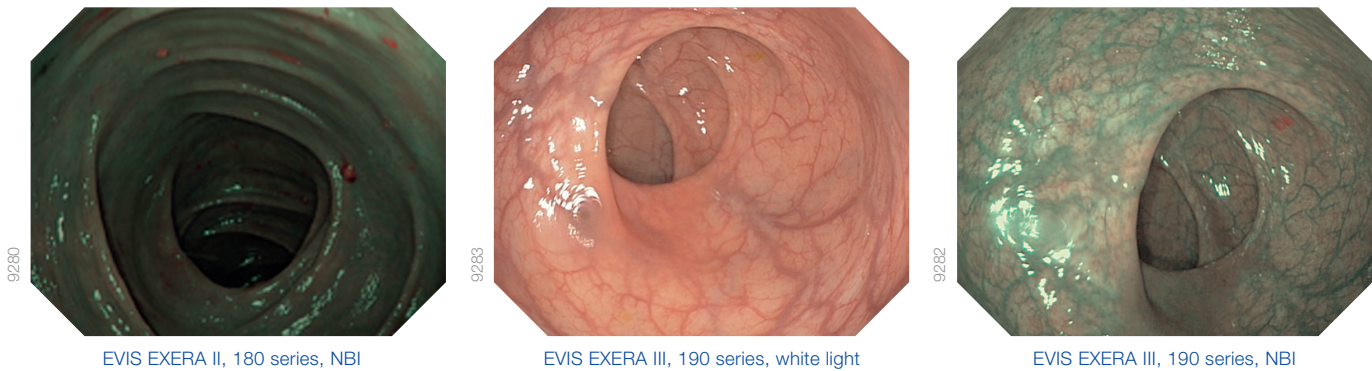


The new HQ190 combines the benefits of zoom endoscopes and current routine endoscopes: High resolving power, a wide field of view, and easy manipulation.



# CREATE HIGH-QUALITY IMAGES

EVIS EXERA III offers a range of technologies that help to achieve outstanding image quality for diagnosis.



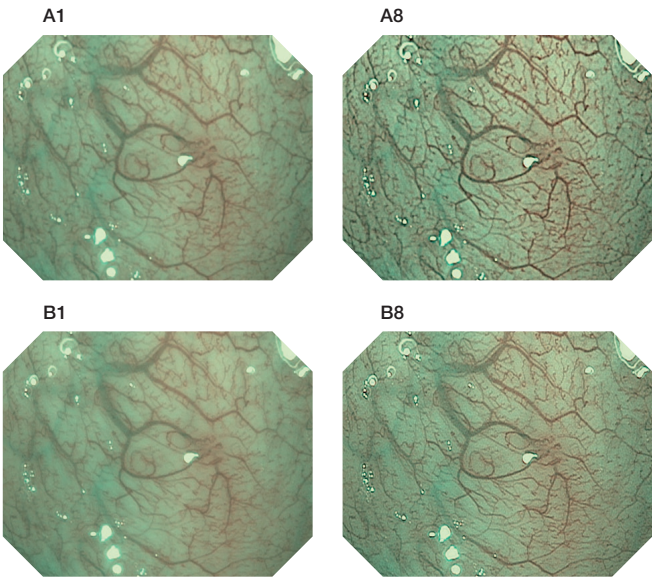
## NBI Images

EVIS EXERA III allows for easy selection between white light and NBI light. As NBI increases the contrast of blood vessels to the surrounding mucosa, it enhances the visualisation of the microvessel architecture. Thus, it has the potential to dramatically improve the detection and characterisation of tissue changes, particularly alterations that are known to be associated with early gastrointestinal cancers and their precursors. Furthermore, NBI with EVIS EXERA III illuminates the lumen twice as far when compared to EVIS EXERA II, so it may open new possibilities for lesion detection during colonoscopy.

## Structural Enhancement

The structural enhancement feature of the video processor CV-190 can increase the effect of NBI. Using an intelligent algorithm, it detects those areas of the image with the highest diagnostic yield and helps to electronically emphasise the detailed pattern. In total, there are 16 settings to choose from: Two modes (A and B Modes) and eight graduations of each (A1 to A8 and B1 to B8). A-mode enhances the overall image, which is particularly suitable for mucosal pattern and pit pattern observation. B-mode enhances fine details, which is optimal for vascular pattern and detailed mucosal pattern observation. To enable rapid switching between different modes and graduations, you

can preselect three settings and program them to one of the endoscope switches and therefore select them with the touch of a button. Extensive tests have shown that the settings A5, A7, and B7 achieve the best results for use with NBI. Therefore, these are the default settings of the CV-190 processor.



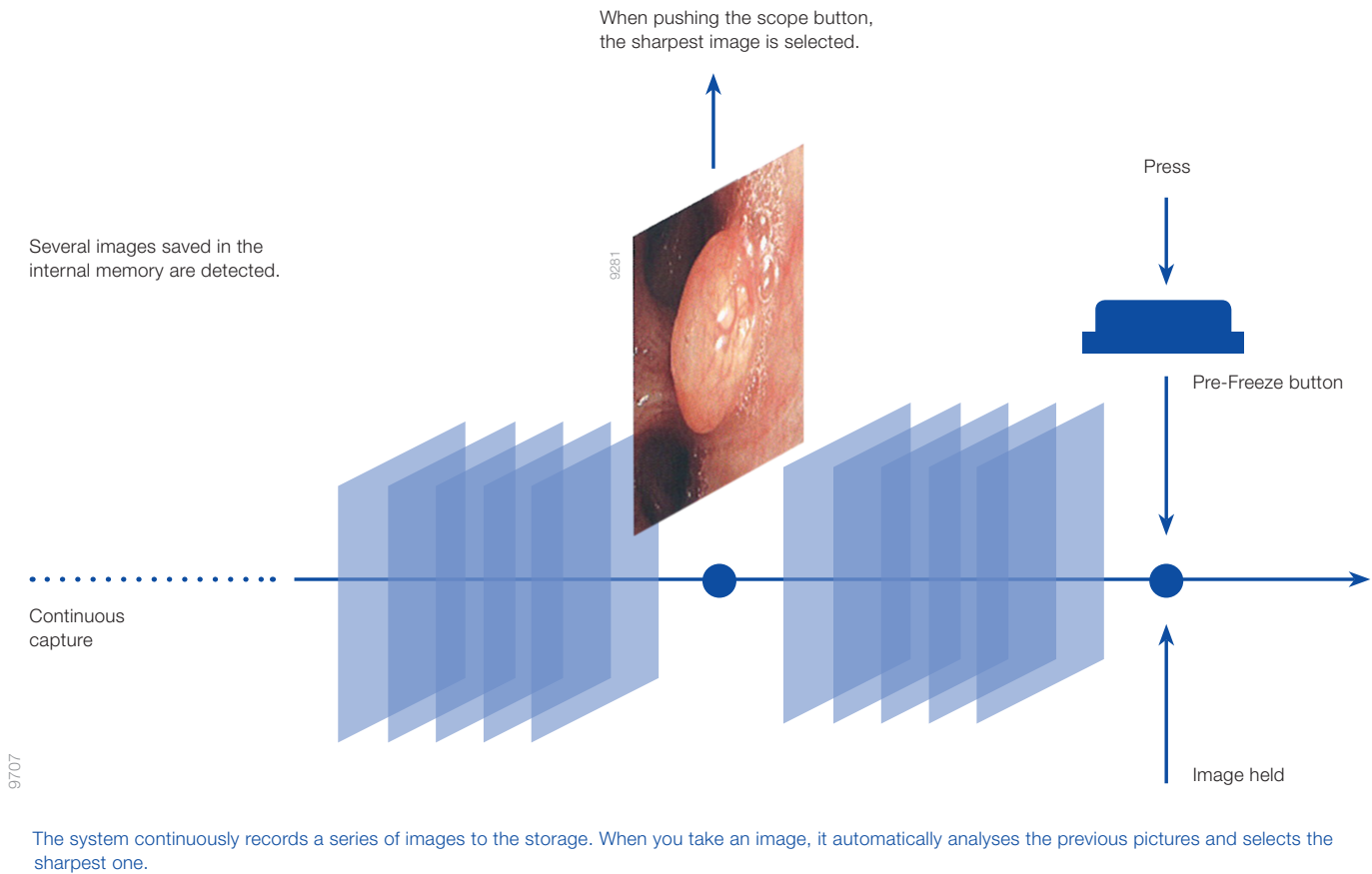
To enhance the display of structures, you can choose among different settings.

## Pre-Freeze

The Pre-Freeze function helps to achieve the sharpest still endoscopic image. During the procedure the video processor continuously saves the most recent video footage and will select the sharpest image whenever you freeze your view. Therefore it is possible to achieve maximum image quality despite movement in the anatomy during a procedure.

## Distal Cap-Assisted Endoscopy

Attaching a distal cap to the endoscope can help to achieve the correct distance and orientation of the endoscope to a lesion. For example in upper GI procedures the heartbeat often affects the wall of the esophagus, the use of distal caps can help steady the endoscope and maintain a set distance between the scope and the lesion.



The system continuously records a series of images to the storage. When you take an image, it automatically analyses the previous pictures and selects the sharpest one.

# NBI-TARGETED BIOPSY IMPROVES DIAGNOSTIC EFFICIENCY OF BARRETT’S OESOPHAGUS SCREENING


Can NBI replace time and cost intensive White Light Endoscopy (WLE) with random biopsies to detect intestinal neoplasia in patients with Barrett’s Oesophagus? Prateek Sharma, et al., compared both technologies in a prospective clinical trial to find the answer.

## What Is the Main Issue when Diagnosing Barrett’s Oesophagus?

The current recommended standard for endoscopic surveillance of patients with Barrett’s Oesophagus (BO) is the Seattle protocol. This method combines white-light endoscopy (WLE) and two kinds of biopsies: four quadrant biopsies, every 2.0 cm, plus targeted biopsies of any endoscopically visible lesions. However the Seattle protocol has several limitations.

On the one hand, the subtle changes of dysplasia and early oesophageal adenocarcinoma (EAC) in patients with BO are often not visible using WLE. On the other hand, performing biopsies randomly has a significant sampling error, as the samples are only taken from a small section of the overall BO segment. Intestinal metaplasia (IM) and dysplasia, in particular, have a patchy distribution.<sup>1</sup> In addition, the biopsy protocol is labour intensive and tedious, with one study showing reduced compliance rate of 51% in the USA. In fact, the longer the BO segment, the lower the compliance to the Seattle protocol.<sup>2</sup>

Therefore, techniques to make screening and surveillance strategies more efficient are highly desirable.



## How Can NBI Help Make the Surveillance of Patients with BO More Efficient?

NBI can help to visualise oesophageal, mucosal, and vascular patterns. This is similar to chromoendoscopy but removes the necessity to spray dye and therefore saves time and costs. Furthermore, the prediction of the presence of IM and dysplasia is feasible using NBI. The aim of the study was to compare high-definition white light endoscopy (HD-WLE) applying the Seattle protocol and NBI targeted biopsy for detection of IM and neoplastic tissue in BO. The authors carried out a prospective, international, randomised controlled trial to examine the difference of HD-WLE and NBI biopsies with respect to (1) the proportion of patients with IM and neoplasia; (2) the proportion of neoplastic area; and (3) the number of overall biopsies performed.<sup>1</sup>

### Medical Benefits of NBI

- Targeted biopsy with NBI is a feasible method for the surveillance of Barrett’s oesophagus
- The use of NBI targeted biopsies may improve the efficiency of screening and surveillance of BO

### Financial Benefit of NBI

- NBI may reduce pathology costs, thanks to fewer biopsies being taken

Open the page at the right to learn more.



RELATED STUDY DETAILS

123 patients with BO randomly underwent upper endoscopy with either HD-WLE – and targeted, as well as random, biopsies according to the Seattle protocol – or NBI targeted biopsies.<sup>1</sup>

Table 1: Histological Yield of HD-WLE and NBI Targeted Biopsies					
	HD-WLE Diagnosis (n)				
	No IM	IM	LGD	HGD	OAC
NBI diagnosis (n)					
No IM	10	14	6	0	0
IM	8	44	11	1	0
LGD	0	10	6	1	0
HGD	1	1	3	4	0
OAC	0	0	0	2	1

NBI, Narrow Band Imaging; IM, intestinal metaplasia; LGD, low-grade dysplasia; HGD, high-grade dysplasia; OAC, oesophageal adenocarcinoma; HD-WLE, high-definition white light endoscopy.

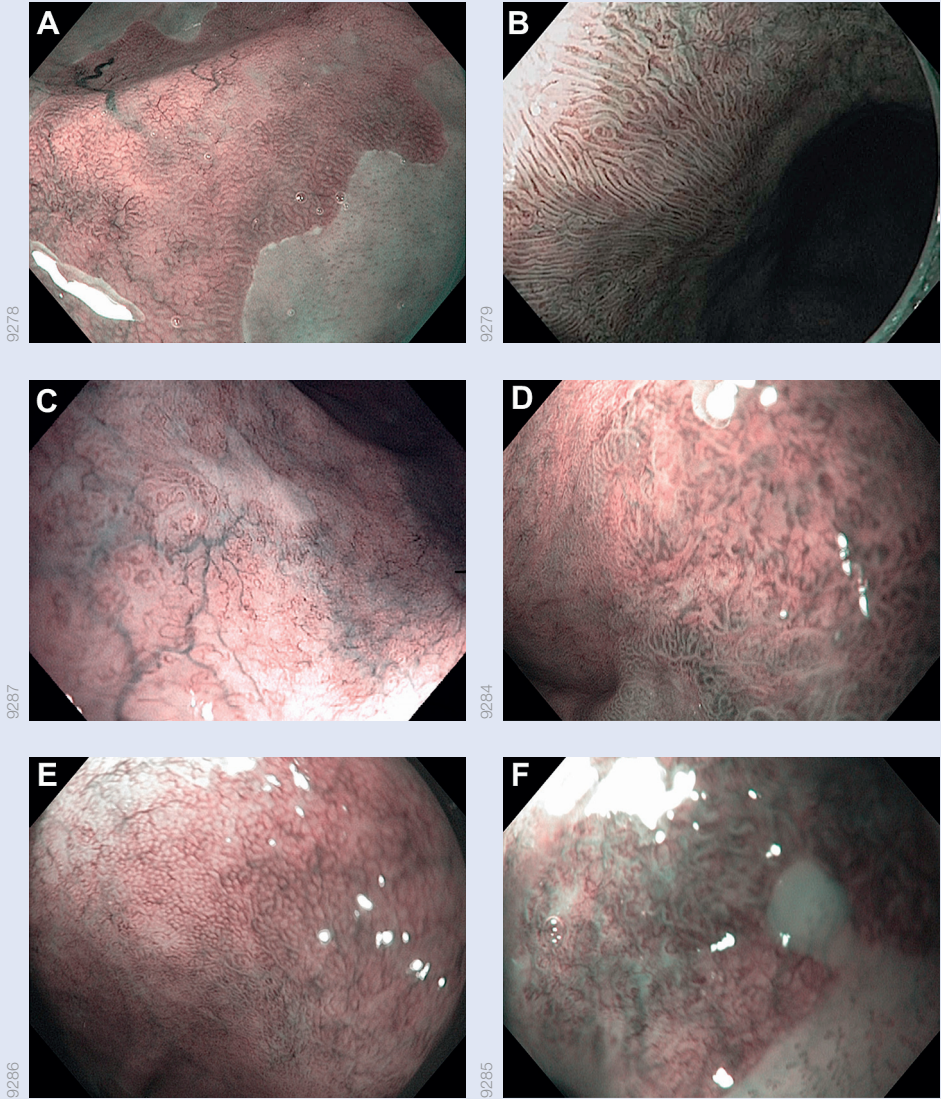
In 65 patients, NBI and HD-WLE obtained the same histological diagnosis.<sup>3</sup>

Results

For detection of IM, HD-WLE and NBI each yielded detection rates of 92%. While HD-WLE required a mean of 7.6 biopsies per patient, NBI only required 3.6 biopsies. For detection of dysplasia, the diagnostic yield of HD-WLE and NBI were equivalent. However, NBI required fewer biopsies than HD-WLE in patients with short-segment BO (3.0 vs 3.9) and patients with long-segment BO (4.1 vs 10.9).<sup>1</sup>

Conclusion

As shown in the study, the diagnostic yield of NBI is equivalent to HD-WLE for detection of neoplastic tissue and/or even superior for detection of IM in BO with fewer biopsies performed. Thereby, NBI can improve the efficiency, as well as save costs, of either BO screening or surveillance in endoscopic practice.<sup>2</sup>



Examples of the different oesophageal surface patterns seen during Narrow Band Imaging: (A) Circular mucosal pattern. (B) Ridged/villous pattern. (C) Absent mucosal pattern. (D) Irregular mucosal pattern. (E) Regular vascular pattern. (F) Irregular vascular pattern.<sup>4</sup>

Source:  
Sharma, Prateek et al., "Standard Endoscopy with Random Biopsies versus Narrow Band Imaging Targeted Biopsies in Barrett's Oesophagus: A Prospective, International, Randomised Controlled Trial," Gut, 62 (1), 2013, 15–21.

<sup>1</sup> pp. 15–16 <sup>2</sup> p. 20; <sup>3</sup> p. 19; <sup>4</sup> p. 17

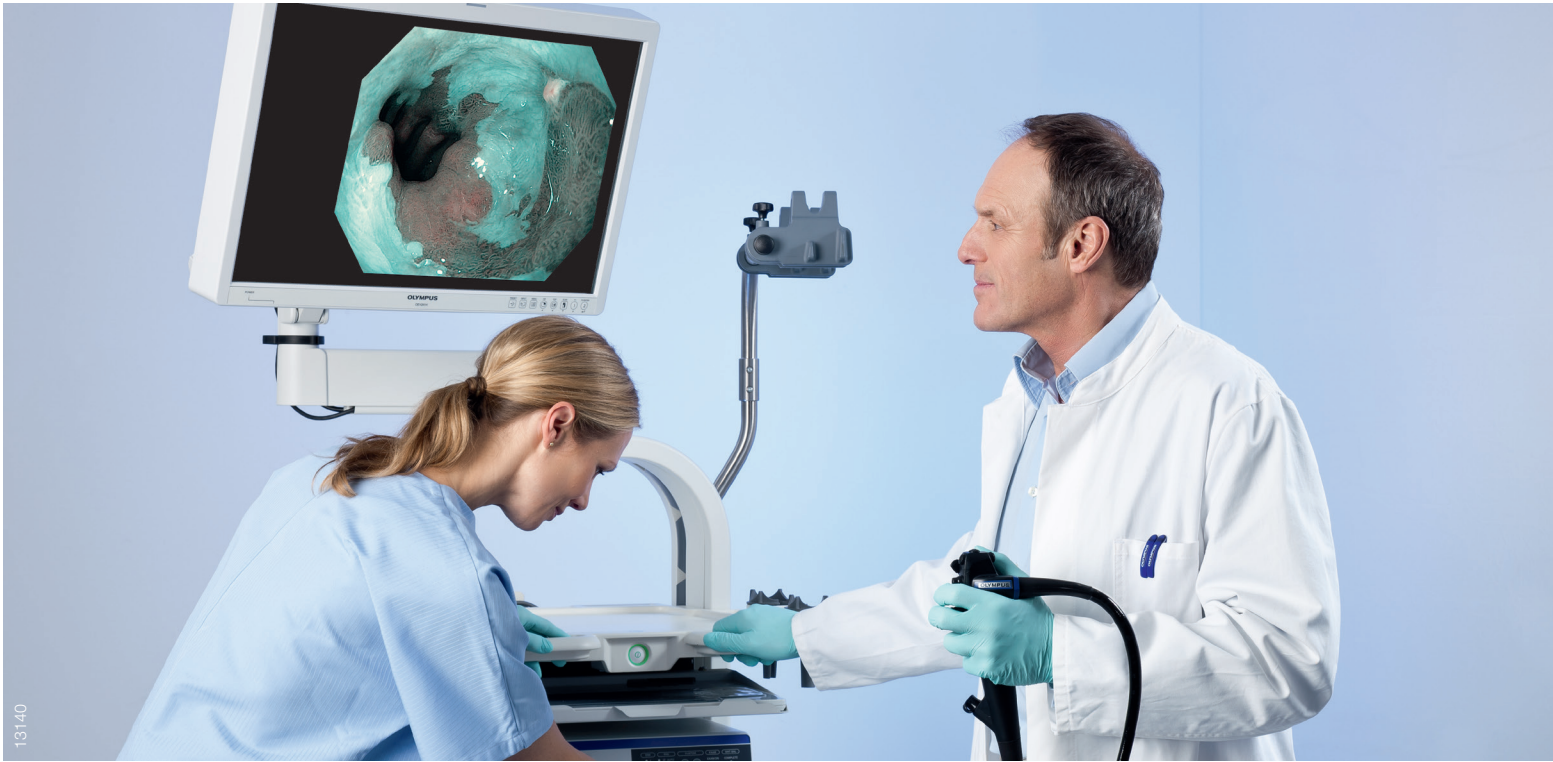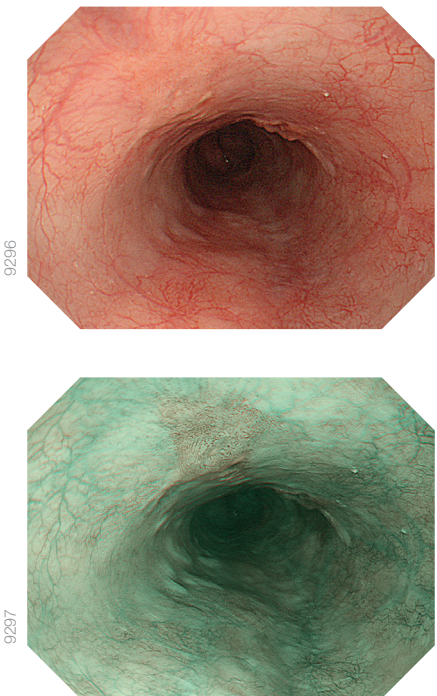
# EARLIER DETECTION OF OESOPHAGEAL CANCER WITH NBI

NBI has the potential to provide a powerful tool for early detection of oesophageal cancer – indicated by a controlled clinical study from Manabu Muto, et al. This section summarizes the most relevant parts of their work.

## What Is the Main Issue when Diagnosing Oesophageal Neoplasia?

Oesophageal cancer is the eighth most common cancer in the world. In 2002, 462,000 new cases were reported. It's ranked number six on the list of the most common causes of cancer-related death, causing 386,000 deaths in the same year. Worldwide the most common histological type is squamous cell carcinoma (SCC), which is also the most common type of head and neck (H&N) cancer. In 2002, H&N cancer totalled 607,000 new cases and 261,000 deaths.

The earlier the cancer is detected, the better the prognosis for the patient, however oesophageal SCC (ESCC) and H&N SCC (HNSCC) are often detected at a late stage, which significantly deteriorates the prognoses. The reasons lie in the difficulty of detecting these cancers by conventional white light endoscopy (WLE). Although Lugol chromoendoscopy can be used for the detection of superficial ESCC, it can cause unpleasant side effects for the patient; for example, severe chest pain and other discomfort.<sup>1</sup> In addition, the Lugol solution is time intensive to prepare and administer. The staining pattern shows wide variations and can makes accurate diagnosis difficult. As this method increases the chance to detect false-positive lesions, it often leads to unnecessary biopsies.<sup>2</sup> In particular for HNSCC, Lugol chromoendoscopy cannot be used at all because of the risk of aspiration.<sup>1</sup>



## How Can NBI Help Enhance the Detection of Oesophageal Cancer?

Because NBI light is absorbed by haemoglobin, it can considerably improve the visualisation of the microvascular structure of the organ surface. This facilitates the identification of early neoplasm in the GI tract. The authors of the study compared the detection rates of ESCC and HNSCC between WLE and NBI to find out whether NBI is more appropriate to detect these cancers at an early stage. Furthermore, they aimed to evaluate the diagnostic accuracy of the two imaging methods.<sup>1</sup>

### Medical Benefits of NBI

- Increased detection rate of superficial cancer as compared to WLE in both the H&N region and the oesophagus
- Easy to apply and easy to understand

### Financial Benefit of NBI

- Faster procedure times as compared to WLE with Lugol staining

Open the page at the right to learn more.



RELATED STUDY DETAILS

To compare the real-time detection yield of superficial SCC and HNSCC cancers between WLE and NBI, a total of 360 patients randomly received primary WLE or primary NBI. In a back-to-back fashion, primary WLE was followed by NBI and vice versa.<sup>1</sup>

Table 1: Detection Rates of Superficial Cancers in the H&N Region and the Oesophagus with WLE and NBI <sup>3</sup>							
Variable	Primary WLE (n = 162)			Primary NBI (n = 158)			P
	No.	%	95% CI	No.	%	95%	
Head and neck region							
No. of superficial cancers	1/13	8	0.2–36.0	15/15	100	78.2 to 100	<0.001
Size of superficial cancer, mm							
<10	0/7	0	0 to 41.0	10/10	100	69.2 to 100	<0.001
11–20	1/5	20	0.5 to 71.6	5/5	100	48.7 to 100	0.12
≥21	0/1	0	0.0 to 0.0	to			-
Oesophagus							
No. of superficial cancers	58/105	55	45.2 to 65.0	104/107	97	92.0 to 99.4	<0.001
Size of superficial cancer, mm							
<10	7/18	39	17.3 to 64.3	17/18	94	72.7 to 99.9	0.03
11–20	7/21	33	14.6 to 57.0	18/19	95	74.0 to 99.9	0.02
≥21	44/66	67	54.0 to 77.8	69/70	99	92.3 to 100	<0.005

Results

While primary NBI detected all (100%) of the superficial cancers in the H&N region, primary WLE detected only 8.0% (Table 1). In the oesophagus, primary NBI detected 97% of the lesions while primary WLE reached only 55%. The detection rate of secondary NBI after primary WLE significantly increased in both the H&N region (8.0% vs 77%) and oesophagus (55% vs. 95%). In contrast, if NBI was followed by secondary WLE, the detection rate declined. **A total of 57% of superficial cancers in the H&N region and even 23% in the oesophagus even were detected by NBI alone.** There was only one lesion that was detected by WLE but was missed by secondary NBI.<sup>3</sup>

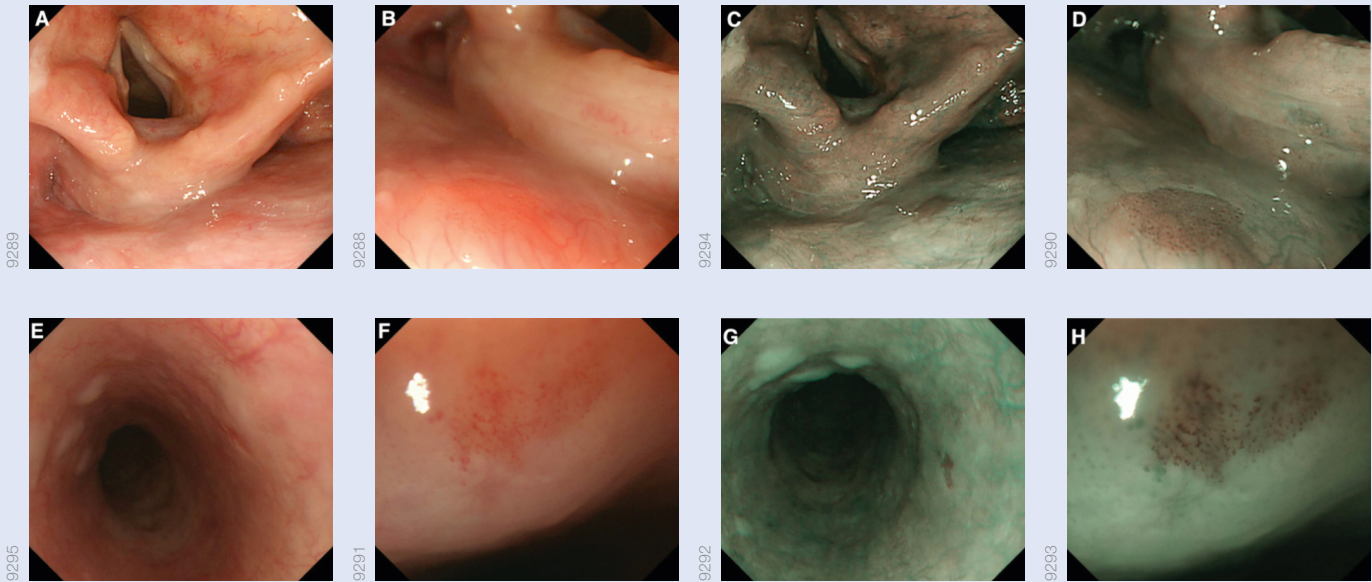
Primary NBI achieved much higher sensitivity and accuracy than primary WLE, whereas the specificity values were similar for both imaging techniques (Table 2). Concerning the positive predictive value, there was no

clear difference between NBI and WLE, but the negative predictive value was again significantly higher for primary NBI than for primary WLE in both regions.<sup>3</sup>

Conclusion

The study showed that the combination of NBI and magnifying endoscopy can significantly improve the detection rates for superficial SCC in the H&N region and the oesophagus. Early detection also increases the potential of minimally invasive treatment; for example, endoscopic or partial surgical resection. NBI can easily be applied with limited experience, but furthermore the learning curve for NBI is shorter than WLE.<sup>4</sup>

NBI reduces the number of unnecessary biopsies and shortens the examination time, when compared to WLE with lugol staining, “NBI is the ideal method for effectively detecting superficial SCC.”<sup>5</sup> The authors even recommend NBI as the standard examination method.<sup>4</sup>



Superficial cancer in the H&N region and oesophagus.  
A: WLE shows a small reddish area (arrows) in the posterior wall of the hypopharynx.  
B: Magnifying WLE shows a slightly reddish area with tiny microdots.  
C: NBI shows a well-demarcated brownish area (arrows) in the posterior wall of the hypopharynx.  
D: Magnifying NBI shows many tiny dots in the brownish area. This lesion was diagnosed histologically as squamous cell carcinoma in situ.  
E: WLE shows a slightly reddish and depressed lesion (arrows) in the oesophagus, although it is difficult to detect by WLE alone.  
F: Magnifying WLE shows a slightly reddish area with an irregular microvascular pattern.  
G: NBI shows a well-demarcated brownish area (arrows).  
H: Magnifying NBI shows many tiny dots in the brownish area. This lesion was diagnosed histologically as high-grade intraepithelial cancer.<sup>6</sup>

Table 2: Performance Rates of WLE and NBI with Regards to Sensitivity, Specificity and Accuracy, for the Diagnosis of Superficial Cancers <sup>3</sup>							
Variable	Primary WLI			Primary NBI			P
	No.	%	95% CI	No.	%	95%	
Head and neck							
Sensitivity	1/13	7.7	0.2 to 36.0	15/15	100	100	<0.001
Specificity	21/22	95.5	77.2 to 99.9	11/14	78.6	54.6 to 98.1	0.28
Accuracy	22/35	62.9	47.6 to 76.4	26/29	86.7	72.6 to 97.8	0.02
	PPV	1/2	50	15/18	83.3	58.6 to 96.4	0.37
	NPV	21/33	63.6	11/11	100	100	0.02
Oesophagus							
Sensitivity	58/105	55.2	45.2 to 65.0	104/107	97.2	92.0 to 99.4	<0.001
Specificity	12/19	63.2	38.4 to 83.7	8/19	42.1	20.3 to 66.5	0.33
Accuracy	70/124	56.5	47.3 to 65.3	112/126	88.9	82.1 to 93.8	<0.001
	PPV	58/65	89.2	104/115	90.4	85.3 to 95.1	0.80
	NPV	12/59	20.3	8/11	72.8	39 to 94	<0.002

Source:  
Muto, Manabu et al., “Early Detection of Superficial Squamous Cell Carcinoma in the Head and Neck Region and Oesophagus by Narrow Band Imaging: A Multicenter Randomized Controlled Trial,” Journal of Clinical Oncology, 28 (9), 2010, 1566–1572.

<sup>1</sup> pp. 1566–1567; <sup>2</sup> p. 1571; <sup>3</sup> pp. 1569–1570; <sup>4</sup> pp. 1570–1571; <sup>5</sup> p. 1570; <sup>6</sup> p.1568



# USE NBI TO ACHIEVE TIME AND COST SAVINGS IN COLONOSCOPY

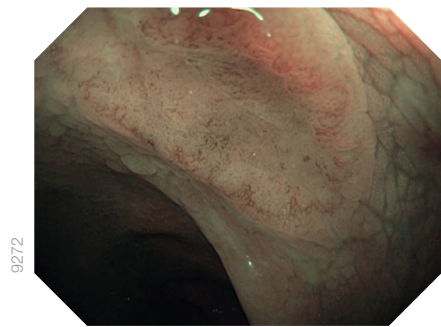
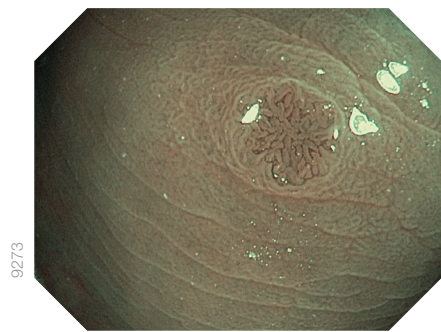
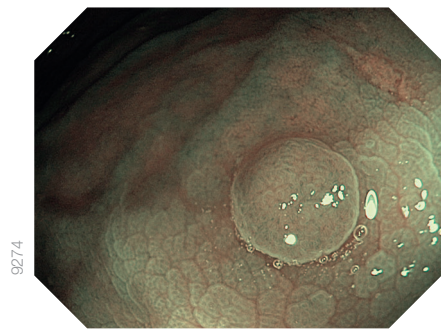
When it comes to the endoscopic examination of the colon, NBI offers substantial advantages. A study recently conducted by David Hewett, et al., has shown tangible benefits for NBI. The authors validated a simple classification system for diminutive polyps.

## What Is the Main Diagnostic Issue with Colonoscopy?

In almost all cases, colorectal polyps that are less than or equal to 5.0 mm are benign. However, current practice requires costly pathological analysis. In particular, the resection and submission of diminutive polyps to pathological assessment are very cost intensive. The greatest potential for reducing costs is the accurate endoscopic differentiation between hyperplastic and adenomatous colorectal polyps.<sup>1</sup>

A promising practice in this regard is the resect-and-discard policy. This approach comprises the classification of diminutive polyps in real time, followed by their resection, and then discarding them without the analysis of a pathologist. Afterwards, the intervals of post-polypectomy surveillance are determined on the basis of two factors: The endoscopic estimation of diminutive polyp histology, and the pathologic report of any larger polyps that are submitted to pathology.

A second cost-saving strategy is to leave in situ hyperplastic polyps. This method comprises the identification of diminutive distal colon hyperplastic polyps in real time by endoscopy. Detected polyps are then left in place without sampling and submission to pathology.<sup>2</sup>



## How Can NBI Help to Reduce the Cost of Colonoscopy?

When tissue becomes neoplastic, the pattern and size of microvessels in the mucosa and submucosa change. NBI has the potential to allow for characterisation of these lesions. As studies have shown, colorectal polyps can be characterised by NBI.<sup>1</sup> In fact, NBI and high-definition colonoscopies can be used to accurately determine the histology and assign surveillance intervals in real time – even without optical magnification.<sup>2</sup>

In order to make NBI useful for clinical practice, simple classification systems are needed, enabling both experienced and inexperienced clinicians to apply NBI.<sup>1</sup>

As a first step towards more targeted therapeutic decisions, the authors of the study developed and established the validity of a practical, simple, NBI-based classification system: The NICE (NBI International Colorectal Endoscopic) classification. This system provides a means for accurate differentiation of diminutive polyps located within the colon.<sup>3</sup>

## Medical Benefits of NBI

- Accurate, in situ, optical diagnosis of diminutive polyps possible
- Possibility to provide faster patient feedback on polyp histology

## Financial Benefit of NBI

- The use of NBI may open new possibilities to reduce the need for conventional tissue sampling in the future

Open the page at the right to learn more.

RELATED STUDY DETAILS

The study aimed to develop a classification for histology prediction. The criteria were then validated by both NBI-untrained fellows and NBI-trained fellows. As a result, the NICE classification was established.

Table 1: The NBI International Colorectal Endoscopic (NICE)*		
Classification* NICE Criterion	Type 1	Type 2
Colour (from vessels)	Same or lighter than background	Browner relative to background (verify colour arises from vessels)
Vessels	None, or isolated lacy vessels coursing across the lesion	Brown vessels surrounding white structures**
Surface pattern	Dark or white spots of uniform size or homogeneous absence of pattern	Oval, tubular, or branched white structures* surrounded by brown vessels
Most likely pathology	Hyperplastic	Adenoma

\* Can be applied using colonoscopes both with or without optical (zoom) magnification.  
\*\* These structures may represent the pits and the epithelium of the crypt opening.<sup>4</sup>

Results

The NICE classification system is based on three simple criteria that were defined to differentiate polyps: colour, vessels, and surface pattern (Table 1). For each criterion, there are clear descriptions for determining the different types of histology, although some polyps will not display all three criteria. This led to a classification of polyps into two types: Type 1 corresponds to the most likely pathology being hyperplastic and Type 2 being adenoma.

Apart from the rating of experts (Table 2), gastroenterology fellows also rated the criteria for each polyp together and subsequently gave an overall prediction of histology (Table 3). Surface pattern reached the highest values in accuracy, sensitivity, specificity, and negative predictive value. When combining the criteria, the presence of adenomatous features achieved an accuracy, sensitivity, and specificity of 91% and a negative predictive value of 92%.<sup>5</sup>

Conclusion

In the study, the classification system performed very well, even when previously NBI-untrained fellows applied it to the set of photographs of polyps. A pilot application during real-time endoscopy obtained similar results.<sup>6</sup>

Thus, if using high-definition colonoscopy with NBI, the NICE classification is suitable to differentiate between hyperplastic and adenomatous polyps. It promises to fulfil the minimum performance benchmarks for assessing the histology of diminutive colorectal polyps in real time. Therefore, the application of this classification can substantially contribute to reducing the cost of colonoscopy.<sup>3</sup>

Table 2: Combined Performance Characteristics of Experts in Predicting Adenomatous Histology in Still Colorectal Polyp Images		
	High Confidence (n = 471) (95% CI)	Low confidence (n = 119) (95% CI)
Accuracy	98.9 (98.0–99.9)	95.9 (94.3–97.5)
Sensitivity	98.0 (94.5–99.4)	94.2 (90.9–96.6)
Specificity	100 (98.3–100)	97.6 (95.2–99.0)
NPV	97.7 (94.8–99.3)	94.4 (91.2–96.7)
PPV	100 (98.5–100)	97.5 (95.0–99.0)

CI, confidence interval; NPV, negative predictive value; PPV, positive predictive value.<sup>5</sup>

Table 3: Performance Characteristics of the NBI International Colorectal Endoscopic Criteria and Overall Classification When Rated by Fellows (n = 19)					
	Accuracy Median (Range)	Sensitivity Median (Range)	Specificity Median (Range)	NPV Median (Range)	PPV Median (Range)
Individual criteria					
Colour	91% (62–95)	92% (25–98)	92% (85–100)	91% (57–98)	92% (86–100)
Vessels	92% (78–97)	92% (59–98)	97% (81–100)	92% (70–98)	95% (83–100)
Surface	92% (82–97)	90% (66–98)	91% (85–100)	91% (74–98)	96% (85–100)
Individual criteria in combination					
Any 2 of 3	92% (75–97)	90% (53–98)	95% (83–100)	91% (67–98)	95% (85–100)
Overall prediction					
All predictions	92% (85–97)	92% (75–98)	95% (78–100)	90% (80–98)	95% (81–100)
High confidence	98% (88–100)	97% (74–100)	100% (79–100)	98% (82–100)	100% (85–100)

CI, confidence interval; NPV, negative predictive value; PPV, positive predictive value.<sup>6</sup>

Table 4: Performance of the NBI International Colorectal Endoscopic (NICE) Classification during Real-Time Colonoscopy for High-Confidence Predictions						
Endoscopist	High-Confidence Predictions, n (%)	Accuracy (95% CI)	Sensitivity (95% CI)	Specificity (95% CI)	NPV (95% CI)	PPV (95% CI)
1	85 (72%)	77/85 91% (82–96)	56/56 100% (94–100)	21/29 72% (53–87)	21/21 100% (84–100)	56/64 88% (77–94)
2	93 (79%)	81/93 87% (79–93)	62/64 97% (89–100)	19/29 66% (46–82)	19/21 90% (70–99)	62/72 86% (76–93)
Combined	178 (75%)	158/178 89% (83–93)	118/120 98% (94–100)	40/58 69% (55–80)	40/42 95% (84–99)	118/136 87% (80–92)

CI, confidence interval; NPV, negative predictive value; PPV, positive predictive value.<sup>6</sup>

Source:  
Hewett, David G. et al., "Validation of a Simple Classification System for Endoscopic Diagnosis of Small Colorectal Polyps Using Narrow Band Imaging," Gastroenterology, 143 (3), 2012, 599–607.

<sup>1</sup> p. 599; <sup>2</sup> p. 605; <sup>3</sup> p. 606; <sup>4</sup> p. 601; <sup>5</sup> p. 602; <sup>6</sup> pp. 603–605

Refer to page 15 for sample images and more information.



# PROMISING PROSPECTS FOR DIAGNOSIS

Much better image quality and more flexibility in less time: NBI with EVIS EXERA III has great potential for diagnosis. This benefits physicians, hospitals and most importantly patients.

## The Future of Endoscopy Has Already Begun

NBI represents a major step forward for the detection and characterisation of gastrointestinal lesions – especially neoplasia. With twice-the-viewable distance, EVIS EXERA III with NBI provides much better insights, particularly into large lumen organs such as the colon and the stomach, and is intended to improve the detection of neoplastic tissue.

As different studies have proven, NBI is not only a useful tool to establish the diagnosis, but NBI may also help to reduce the necessity for tissue sampling or, in the future, even avoid biopsy. Thus, it can help to save time and money while simultaneously safeguarding procedural quality – which translates to tangible benefits for the hospital and the patient.


To ease usage in daily clinical routines, proprietary Dual Focus technology offered in EVIS EXERA III HQ series endoscopes helps to easily visualise the mucosa and thus helps to make decisions regarding biopsies or where to delineate a lesion for further treatment.

In addition, NBI can be used before and after interventional procedures. NBI is ideal for determining the extent of vessels, as well as lesions, before treatment. But it is also suitable to follow up vascularisation of the operated area and its circumference.

### Major Benefits of NBI at a Glance

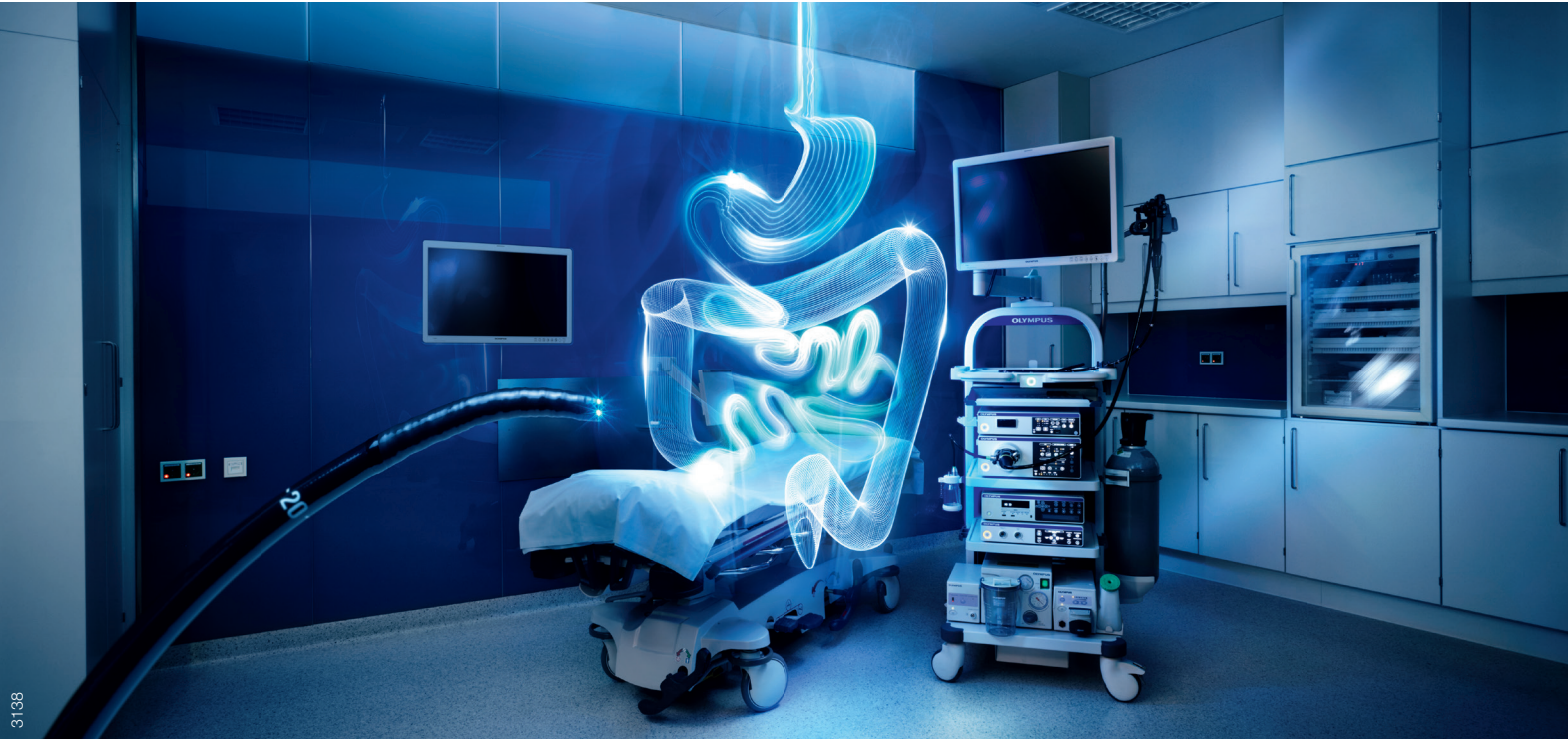- Helps to visualise mucosal and vascular patterns to facilitate early detection
- Depending on location, it is equivalent or even better than WLE while reducing the number of biopsies and thus expected to be more cost effective

# DIAGNOSIS TRAINING PORTAL



Olympus is committed to providing the most advanced technologies for endoscopic diagnosis and treatment, assisting you in enhancing patient care. As part of this commitment, we are currently developing a range of training materials to help you get the most from your Olympus endoscopic technologies.

Coming soon! EndoAtlas – a central online resource providing you with an array of case material from the entire gastrointestinal tract. EndoAtlas contains high-resolution images and detailed case reports, making it a valuable tool for education, training, and skill development in the areas of optical diagnosis and Narrow Band Imaging.





[www.nbiatlas.com.au](http://www.nbiatlas.com.au)

Specifications, design, and accessories are subject to change without any notice or obligation on the part of the manufacturer.

## OLYMPUS

Published by:

**OLYMPUS EUROPA SE & CO. KG**

Postbox 10 49 08, 20034 Hamburg, Germany  
Wendenstrasse 14-18, 20097 Hamburg, Germany  
Phone: +49 40 23773-0, Fax: +49 40 233765  
[www.olympus-europa.com](http://www.olympus-europa.com)

Local Contacts:

**OLYMPUS AUSTRALIA PTY LTD**

3 Acacia Place, Notting Hill, VIC 3168  
Phone: 1300 132 992  
Web: [www.olympusaustralia.com.au](http://www.olympusaustralia.com.au)  
ABN: 90 078 493 295

**OLYMPUS NEW ZEALAND LTD**

15D Paul Matthews Rd, Albany, Auckland NZ 0632  
Phone: 0508 6596787  
Web: [www.olympus.co.nz](http://www.olympus.co.nz)  
Company No.: 910603