



Wagner SL Revision® Hip Stem

Surgical Technique



Femoral Revision Prosthesis
for Extensive Bone Loss

Disclaimer

This document is intended exclusively for experts in the field, i.e. physicians in particular, and is expressly not for the information of laypersons.

The information on the products and/or procedures contained in this document is of a general nature and does not represent medical advice or recommendations. Since this information does not constitute any diagnostic or therapeutic statement with regard to any individual medical case, individual examination and advising of the respective patient are absolutely necessary and are not replaced by this document in whole or in part.

In the event that this document could be construed as an offer at any time, such offer shall not be binding in any event and shall require subsequent confirmation in writing.

Wagner SL Revision Hip Stem Surgical Technique

Table of Contents

Concept	1
Preoperative Planning	2
Assessment of Bone Loss and Component Selection	2
Determination of Leg Length	3
Determination of Femoral Offset and Abductor Muscle Tension	3
Templating	4
Surgical Technique	5
Surgical Approach Factors	5
Posterior Approach	6
Trochanteric Slide and Extended Trochanteric Osteotomy	7
Trochanteric Slide	7
Extended Trochanteric Osteotomy	8
Determination of Intra-operative Leg Length	9
Component Removal	9
Preparation of the Femoral Canal	10
Trial Reduction	11
Insertion of the Stem	13
Femoral Head Assembly	13
Wound Closure	13
Postoperative Management	13
Case Studies	14
Case Study of Transfemoral Approach	14
Case Study of Periprosthetic Fracture	15
Case Study of Endofemoral Approach	16
Case Study of Nine-Year Result	17
Implants	18
Instruments	21

Concept

Since its introduction in 1986, this reliable and user-friendly stem system has been implanted successfully in more than 85,000 cases.^{1,2} The positive outcomes achieved by surgeons from around the world are reflected in a large number of clinical publications.^{1,2,3} These studies are a testament to the high quality and reliability of the *Wagner SL Revision Hip Stem* with its unique osteophilic design.

The time-tested geometry of the *Wagner SL Revision Stem* has received only minimal design upgrades in its long history. With a focus toward enhancing the lateral stem geometry to increase the area for osseointegration, the latest version, the *Wagner SL Revision Stem*, is well positioned for continued clinical success.

The *Wagner SL Revision Stem* is a *Protasul*[®]-64 titanium alloy stem designed for uncemented fixation in femoral revision surgery. A 2° tapered stem with a circular cross-section, the *Wagner SL Revision Stem* can be placed in any version by the surgeon.

The *Wagner SL Revision Stem* has 8 longitudinal ribs with relatively sharp ridges that are intended to engage the femoral cortex, thus enabling optimum rotational stability.¹ The combination of the longitudinal ribs and tapered geometry provides secure fixation reducing the incidence of thigh pain associated with some uncemented prosthetic systems.² In addition to providing rotational stability, the longitudinal ribs are also beneficial for bony apposition. Clinical studies have shown very clearly that bone forms and attaches preferentially on the sharp-edged prominences of the implant.³

Stem length along with the secure fit of the taper design and the torsionally resistant ribs provide firm fixation to the healthy bone distal to the original prosthetic bed. This helps to bridge the fixation region of the previous implant and provides mechanical stability. With time, there is often active ossification in the old prosthetic bed and the replacement of lost bone.³

- 1 Bühler D., Berlemann U, Lippuner K, Jaeger P, Nolte L. Three-dimensional primary stability of cementless femoral stems. *Clinical Biomechanics*. 1997; 12: 75–85.
- 2 Wagner H., Wagner M. Cone Prosthesis for the hip joint. *Arch Orthop Trauma Surg*. 2000; 120: 88–95
- 3 Schenk R.K., Wehrli U. Zur Reaktion des Knochens auf eine zementfreie SL-Femur-Revisionsprothese. *Orthopade*. 1989; 18: 454–462.



Preoperative Planning

The objectives of preoperative planning include:

1. Assess amount of bone loss to:
 - Select appropriate implant to reconstruct the femur.
 - Determine any special needs such as allograft or adjunctive fixation (cables, wire, plates, etc.)
2. Determine the anticipated component size necessary to provide structural stability.
3. Establish parameters of joint kinematic restoration that include:
 - Determination of leg length.
 - Restoration of offset for abductor muscle tensioning.
4. Assess the acetabulum to determine if any acetabular reconstruction is needed and consider the potential impact of the acetabular reconstruction on the femoral side.

Assessment of Bone Loss and Component Selection

To select the appropriate type of implant in femoral revision surgery, a number of factors must be evaluated.

Reconstructing the femur based on the amount of femoral bone loss and the status of the remaining bone is important in determining the appropriate prosthesis.

The *Wagner SL Revision Stem* is a versatile device that can address a wide range of femoral revision needs. The stem is a logical choice for Type II and Type III femoral bone deficiencies, and can also be used with certain Type I and Type IV deficiencies. The final implant choice will depend on the individual patient and the surgeon's fixation preference.

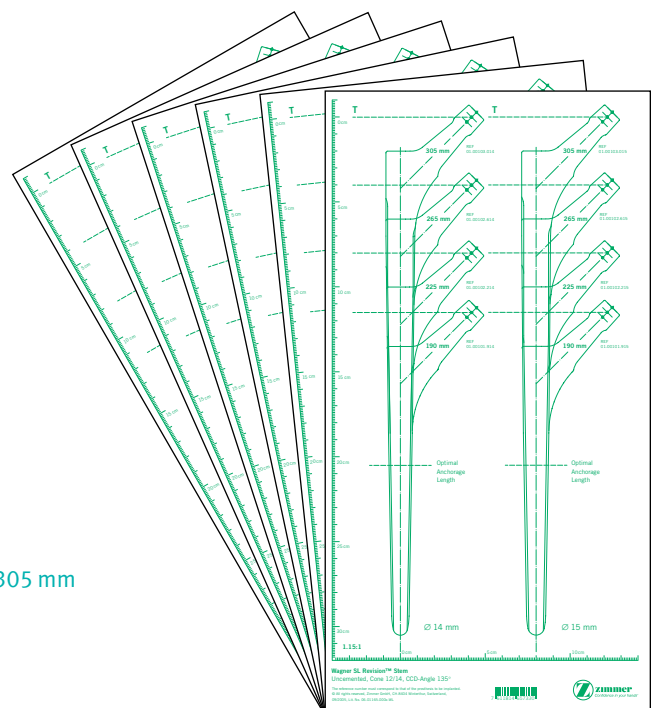
When selecting the appropriate size *Wagner SL Revision Stem*, it is important to understand that when prepared properly, the femur will allow for close contact between the middle third of the implant and the femoral cortex and not just a tight fit at the tip of the stem in the medullary canal.

Selection of the correct stem diameter is particularly important. **The most common mistake is choosing a stem diameter that is too small. Such a decision can result in secondary subsidence of the prosthesis.** The outline on the template corresponds exactly to the dimensions of the implant.

In choosing the diameter, it must be remembered that reaming removes a thin layer of bone and the sharp longitudinal ribs cut slightly into the bone during insertion. **The outline of the stem on the template must therefore overlap the inner outline of the cortex in the region of the middle third of the stem by 1 mm on each side.**

X-ray templates can be obtained under Item Numbers:

Item No.	Diameter	Lengths
06.01165.000x	14 mm–25 mm	190 mm, 225 mm, 265 mm and 305 mm
94.00.52x	14 mm–25 mm	345 mm



It is also important to have adequate stem length in order to bypass any femoral defects. When bypassing a cortical defect, the implant should extend past the defect by a minimum of two and one-half times the measured canal diameter to provide adequate support. In addition, it is important for the tip of the stem to extend into the intact medullary canal at least 7 cm distal to the end of the previous prosthetic bed.

Note: If the *Wagner SL Revision Stem* is only anchored in the region of the tip of the stem or the zone of anchorage measures less than 7cm, there is a risk of material fatigue.

Determination of Leg Length

Preoperative determination of leg length is essential for the restoration of the appropriate leg length during surgery. In femoral revision surgery, correction of leg length discrepancy is usually necessary because of bone and soft tissue changes resulting from the failed prosthesis.

An anterior/posterior (A/P) pelvic radiograph often provides enough detail of leg length inequality to proceed with surgery. If additional information is needed, a full-length femoral x-ray view may be helpful. From the clinical examination and radiographic information on leg length, the needed correction, if any, can typically be determined.

If leg length is to be maintained or minimally increased, it is usually possible to perform the operation successfully without osteotomy of the greater trochanter, unless extensive exposure of the acetabulum or femur is necessary. However, if there is some major anatomic abnormality, osteotomy of the greater trochanter may be helpful and offers additional safety.

In the unusual situation where the limb is to be significantly shortened, subtrochanteric osteotomy, or osteotomy and advancement of the greater trochanter are mandatory. If the limb is shortened without one of these techniques, the abductors will be lax postoperatively, and the risk of dislocation will be high. Also, gait will be compromised by the laxity of the abductors.

Determination of Femoral Offset and Abductor Muscle Tension

After establishing the desired leg length requirements, abductor muscle tensioning through femoral offset must be considered. Restoring abductor tension places the abductor muscles at their optimal mechanical advantage and results in improved functioning with less chance of dislocation and limp.

When the patient has a very large offset between the femoral head center of rotation and the line that bisects the medullary canal, the insertion of a femoral component with a lesser offset will, in effect, medialize the femoral shaft. To the extent that this occurs, laxity in the abductors will result.

Another method to restore or compensate for offset is by osteotomy and advancement of the greater trochanter to increase tension in the abductor muscles. In addition, the use of special acetabular liners can change the placement of the joint center of rotation.

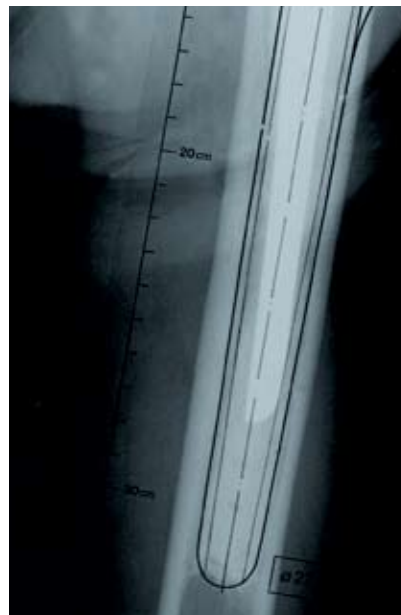Using the *Wagner SL Revision Stem Templates* (Lit. # 97-0102-050-00) on the preoperative x-ray film allows the surgeon to estimate the amount of offset needed for the new femoral component.

Templating

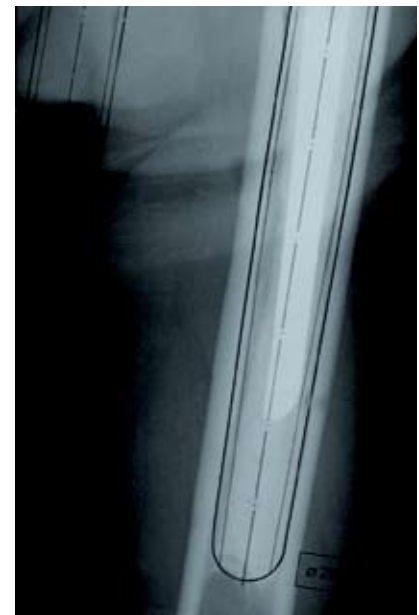Preoperative planning for the insertion of the *Wagner SL Revision Stem* requires at least two views of the involved femur; an A/P view of the of the pelvis centered on the pubis symphysis and a Lowenstein lateral view on an 11" x 17" cassette. Both views should show the full length of the femur. In addition, it may be helpful to obtain an A/P view of the involved side with the femur internally rotated. This compensates for naturally occurring femoral version, and provides a more accurate representation of the true medial-to-lateral dimension of the metaphysis.

When templating, the magnification of the femur will vary depending on the distance between the x-ray source and film and the distance between the patient to the film. The *Wagner SL Revision Stem* Templates use 20 percent magnification, which is near the average magnification on most clinical x-rays. Large patients and obese patients may have magnification greater than 20 percent because osseous structures are farther away from the surface of the film. Likewise, smaller patients may have magnification less than 20 percent. If necessary and to better determine the magnification of any x-ray film, use a standardized marker at the level of the femur. (Templates of other magnification can be obtained as a special order by contacting your Zimmer Sales Representative.)

Preoperative planning is important in choosing the acetabular component if it is also being revised. Acetabular preoperative planning is beyond the scope of this document but must be considered in conjunction with the *Wagner SL Revision Stem*. Please refer to the *Zimmer® Trabecular Metal™ Revision Shell Surgical Technique* for more information.



Determination of the appropriate stem diameter with the planning template. The contour of the template lies on the contour of the cortical bone. This stem diameter is too small.



With the correct stem diameter, the contour of the template must overlap the contour of the cortical bone by 1 mm.

Surgical Technique

Surgical Approach Factors

When determining which surgical approach is appropriate for a specific revision patient, a number of factors must be considered. The two most important factors are: 1) the difficulty of component removal and 2) the complexity of the reconstruction. Other considerations include prior approaches and leg length discrepancy.

There are advantages and disadvantages with all approaches used in hip surgery. It is important that the surgeon be proficient with several different approaches to individualize the approach to patient needs.

A direct lateral (transgluteal) or anterolateral approach may be used when component removal is straightforward and reconstruction is not complex. The posterior approach provides better exposure for more difficult revisions, and it can easily be converted into a trochanteric osteotomy.

A transverse trochanteric osteotomy provides the best pelvic exposure and very good femoral exposure, but there is a high incidence of trochanteric nonunion and escape. A trochanteric slide provides better femoral exposure and, because the abductors and the vasti remain attached to the trochanter as a sling, there is less risk of trochanteric escape. If more pelvic exposure is required, a trochanteric slide can be converted to a transverse osteotomy by releasing the vasti.

The extended trochanteric osteotomy provides the best femoral exposure and may be used when difficulty in removing the femoral component is anticipated. The extended osteotomy and the slide also provide adequate pelvic exposure for complex acetabular reconstruction, but neither provides as much pelvic exposure as the transverse trochanteric osteotomy which provides the best access to the ilium and the anterior and posterior columns.

Removal of a protrusio acetabular cup can be difficult. Use extreme caution if the cup is adjacent to pelvic vessels or viscera. Preoperative angiography, CT, or IVP may be required, and a trans-trochanteric approach is usually necessary.

On the femoral side, cemented long stem or porous-coated long stems are the most difficult to remove. To facilitate removal of these components, a trochanteric osteotomy may be performed.

If a complex acetabular reconstruction is necessary because of loss of bone stock, the exposure should extend from the ilium to the ischium. This may require a posterior approach and may also require a trochanteric osteotomy. Likewise, a complex femoral reconstruction may be accomplished more easily and without risk of fracture if a trochanteric approach is used.

If the leg must be lengthened more than 3cm, a trochanteric osteotomy will facilitate the procedure. If difficulty in reattachment is anticipated, then a trochanteric slide or an extended trochanteric osteotomy may be used. A subtrochanteric shortening osteotomy is also often advantageous.

Posterior Approach

Use a posterior approach as part of the trochanteric slide or the extended trochanteric osteotomy. It can also be used for a transverse osteotomy, although this is more commonly accomplished through a lateral approach. Make the skin incision parallel to the femoral shaft to just proximal to the tip of the greater trochanter. Then curve the incision posteriorly toward the posterior iliac spine. Incise the fascia lata to expose the greater trochanter, abductors, and vastus lateralis. In some complex cases, it is necessary to expose the anterior capsule directly. To do this, place the hip in abduction and external rotation, identify the anterior boarder of the gluteus medius, and retract it posteriorly. Perform an anterior capsulectomy. Identify the interval between the gluteus minimus and gluteus medius. Then place the hip in internal rotation and flexion.

Retract the posterior borders of the gluteus medius and gluteus minimus anteriorly, and identify the external rotators. The silver-white tendon of the piriformis forms the most superior part of the external rotators and serves as a landmark. Detach a flap from the greater trochanter. This flap should consist of the external rotators beginning at the piriformis and extending distally to the quadratus femoris. The flap may also include the quadratus femoris. Tag the flap with a suture for later repair.

Perform a posterior capsulectomy and dislocate the hip posteriorly. This may be enough exposure but, if more is required, proceed to either a trochanteric slide or an extended trochanteric osteotomy. If more extensive posterior exposure is required, incise the proximal part of the gluteus maximus tendon and mark it with a suture for later repair. The sciatic nerve can be identified at this point and is thereafter protected by the flap of external rotators.

Trochanteric Slide and Extended Trochanteric Osteotomy

Both the trochanteric slide and the extended trochanteric osteotomy involve developing the interval between the vastus lateralis and the posterior septum. Reflect the vastus lateralis anteriorly; maintaining the attachment to the vastus lateralis ridge in continuity with the greater trochanter. This anterior reflection should not exceed one centimeter as it is important to leave the proximal fragment vascularized.

Trochanteric Slide

For the trochanteric slide, use an oscillating saw or osteotome to perform the osteotomy from posterior to anterior in the sagittal plane. The osteotomy cut should exit just distal to the vastus lateralis ridge. This will leave the trochanteric fragment enclosed in a sling of muscle consisting of the abductors proximally and the vastus lateralis distally. This allows for stable reattachment and decreases the potential for trochanteric escape.

If desired, the trochanteric fragment can be made thick to include the gluteus medius and minimus. To accomplish this, angle the osteotomy anteromedially. Alternatively, the osteotomy can include the gluteus medius only, leaving the gluteus minimus attached to the femur. This will create a thinner fragment. Then, after making the osteotomy cut, dissect the gluteus minimus off the femur. It can be repaired later along with the external rotators. Having the gluteus minimus detached from the trochanteric fragment allows easier and more stable reattachment of the trochanteric fragment. If left attached to the trochanteric fragment, the gluteus minimus tethers the fragment anteriorly.

Retract the trochanteric fragment and its attached muscles anteriorly. Then use a large self-retaining retractor to dislocate the hip posteriorly in adduction and internal rotation.

To reattach the greater trochanter, use two cerclage wires through the lesser trochanter, or through the medial femoral cortex and the greater trochanter. If the trochanter is fragile, place the wires around the trochanter rather than through the drill holes. Then repair the external rotators and the gluteus minimus, and suture the vastus lateralis back to the septum.

Extended Trochanteric Osteotomy

For an extended trochanteric osteotomy, the osteotomized fragment is much thicker, includes the entire trochanter, and extends into the diaphysis.

The fragment includes the insertion of the gluteus medius and gluteus minimus and involves approximately one-third of the diameter of the femur. The distal extent of the osteotomy depends on the length and fixation of the component to be removed and is determined from preoperative templating. The osteotomy should not extend into the metaphysis or stem fixation may be difficult to achieve. It is optimal to retain at least 5cm of diaphyseal femur beyond the osteotomy.

Because the osteotomy involves one-third of the circumference of the femur, it is more easily performed after the hip has been dislocated and the femoral component removed. Typically, however, this is not possible because this approach is often being done to facilitate implant removal. In addition, if dislocation is difficult, the osteotomy should be done first.

Use the posterior approach and reflect the vastus lateralis off the septum; being careful to identify and cauterize perforating vessels. Limit the anterior reflection of the vasti muscles off the septum to about 1cm or just enough to allow access for an oscillating saw or a high-speed burr. It is important to keep the muscle and the blood supply it brings attached to the long bony fragment.

With the hip in slight internal rotation, use an oscillating saw to perform the posterior limb of the osteotomy. Proximally, angle the saw blade medially to include all of the greater trochanter. Continue the cut distally on the posterolateral femur just anterior to the linea aspera. The osteotomy should not exceed one-third the diameter of the proximal femur if the femoral component is still in place. Keep the distal horizontal end of the osteotomy rounded. If the femoral implant is small, it may be possible to make both the posterior and anterior cuts by passing the blade from posterior to anterior across the canal. If this is not possible, then use a narrow osteotome to weaken the anterior cortex after the posterior cut is made. Make multiple perforations through the muscle anteriorly without stripping it. This will keep the vastus lateralis attached and the fragment vascularized. To avoid fracturing the greater trochanter, release the capsule anteriorly before levering the osteotomy open. Then, use multiple osteotomes to gently pry the osteotomy open from posterior to anterior; keeping the vastus lateralis attached. Retract the fragment anteriorly and remove the prosthesis.

A long, porous-coated implant may still be quite solid after the osteotomy has been completed because of bony ingrowth on the medial side. This can be broken down with thin osteotomes or with a Gigli saw. If the distal part of the implant has not been exposed by the osteotomy then it may be necessary to section the implant at the distal aspect of the osteotomy and use a trephine to remove the distal stem.

Use a burr to shape the osteotomy fragment to fit the new prosthesis before reattachment. Use multiple (usually three or four) double-looped cerclage wires or *Zimmer Cable-Ready*[®] cables. Apply any available bone graft to the posterior osteotomy and suture the vastus lateralis back to the septum. If the osteotomy is not stable, use a cortical strut allograft to reinforce it. Abductor laxity can be addressed by shortening the osteotomy fragment and advancing it. When testing range of motion, be careful to avoid anterior impingement of the osteotomized fragment.

Determination of Intra-operative Leg Length

Establish landmarks and obtain measurements before dislocation of the hip so that, after reconstruction, a comparison of leg length and femoral shaft offset can be obtained. From this comparison, adjustments can be made to achieve the goals established during preoperative planning.

There are several methods to measure leg length. Use the *Zimmer* Joint Ruler, or a device/method that is most familiar. Take baseline measurements, then compare adjustments made intra-operatively to the preoperative plan. It is very important to use a reliable method of leg length assessment, particularly in femoral revision surgery, as traditional bony landmarks, such as the tip of the Greater Trochanter, may not be present.

Component Removal

At times, various types of trochanteric osteotomies can facilitate femoral component removal. Removal of a well-fixed cemented component is a challenge for any surgeon. It is difficult to extract the implant from the femur while minimizing the risk of fracture and loss of existing bone stock. Avoiding perforation of the femur while removing the old bone cement is also a challenge. Removing a polished or smooth cemented femoral prosthesis is typically easier than removing a device that has a roughened surface. The use of thin osteotomes proximally helps remove overgrown bone and loosen the bone cement. If the component is difficult to extract, it is helpful to remove as much cement as possible laterally to help minimize the chance of fracturing the trochanter.

Once a cemented femoral component is extracted, completely remove the remaining bone cement from the femur. Remove the cement from proximal to distal, including the distal cement plug, if present. This can be accomplished with hand instruments, ultrasound systems, or any other suitable cement removal instruments. In difficult cases, an extended trochanteric osteotomy will provide excellent visualization and access for complete cement removal.

To remove a proximally porous-coated femoral implant, disrupt the proximal implant/bone interface and extract the stem using the extraction hole or by securing the taper as mentioned previously. A trochanteric osteotomy may facilitate removal of a well-fixed and ingrown proximal porous device. Use high-speed power tools or a Gigli saw to loosen the areas of bone ingrowth anteriorly, posteriorly, and medially.

Removal of an extensively porous coated femoral prosthesis is a more difficult task. An extended trochanteric osteotomy is frequently required. Disrupt the proximal fixation as described above. At times, the implant must be cut at the junction of the proximal body flare and the cylindrical distal stem with a high-speed metal-cutting instrument. After removing the proximal portion of the implant, use a trephine to ream over the top of the distal portion of the stem to break the interface between the implant and bone.

Preparation of the Femoral Canal

After careful removal of the previous implant and any associated cement, the medullary canal of the femur is gradually reamed by attaching the T-handle (75.00.25) to the reamer (01.00109.014/025), starting with a size that is 4-5mm smaller than the templated size and reaming past the depth of the previous prosthetic bed. There are engraved lines (Fig. 1) on the reamer that correspond to the head center of each implant length using a +0mm femoral head.

The reamers are introduced to a depth where the mark that corresponds to the length of the stem is level with the tip of the greater trochanter (Fig. 2). The appropriate stem diameter has been reached when the resistance to reaming is markedly increased. The intended length of the prosthesis is determined during pre-operative planning.




Fig. 1



Fig. 2

Trial Reduction

To assess leg length, abductor muscle tension and joint stability, perform a trial range of motion using a trial stem. To assemble the trial prosthesis, 3 components are used: 1) the Distal Stem Trial (01.00109.114/125) 2) the Proximal Stem Trial that represent the four stem lengths (01.00109.810,802/804) and 3) the Proximal Trial Screw used for each respective stem trial length (01.00109.809,805/807) (Fig. 3).



Fig. 3

Based on the final reamer diameter and the length as indicated by the engraved line, assemble the trial stem by placing the appropriate Proximal Trial Screw through the Proximal Stem Trial. Then use the small Hex Wrench (79.15.84) to tighten the Proximal Stem Trial onto the Distal Stem Trial.

To insert the assembled trial stem, use the Impactor/Extractor (01.00109.808) by lining up the key on the inserter with the keyed portion of the trial stem (Fig. 4), and turn the end of the inserter until the threads are fully engaged.




Fig. 4

Place the assembled trial stem into the femoral canal, and carefully but firmly seat the trial using moderate strikes of the mallet. If it is difficult to seat the trial stem, there may be a need for additional reaming to remove any impinging bone. Assess the fit again with the trial stem.

Remove the stem inserter from the trial and attach the appropriate trial head. The *Wagner SL Revision Stems* are compatible with a variety of femoral heads, examples including *VerSys*[®], legacy Centerpulse and BIOLOX[®]+ Delta Ceramic Femoral Heads. (Please visit www.productcompatibility.zimmer.com for a complete listing of approved femoral heads.) However, there are restrictions as to the head-neck lengths that can be used (**head-neck lengths greater than +4mm are not approved for use on 14 and 15mm diameter Wagner SL Revision Stems.**) The chart on the right outlines selected heads that are approved for use with the *Wagner SL Revision Stems*.

Perform the trial range of motion to verify that leg-length, femoral offset, femoral version, and joint stability are optimal. Remove the trial head and securely re-attach the Impactor/Extractor. Strike the underside of the Inserter/Extractor handle to remove the trial stem.

VerSys Head/Neck Length (all diameters)

00-8018-0XX-XX Catalog Numbers

Stem Diameter	-3.5mm	+0mm	+3.5mm	+7mm	+10.5mm
14mm	Yes	Yes	Yes	No	No
15mm	Yes	Yes	Yes	No	No
16mm	Yes	Yes	Yes	Yes	No
17mm	Yes	Yes	Yes	Yes	No
18mm	Yes	Yes	Yes	Yes	No
19mm	Yes	Yes	Yes	Yes	No
20mm	Yes	Yes	Yes	Yes	No
21mm	Yes	Yes	Yes	Yes	No
22mm	Yes	Yes	Yes	Yes	No
23mm	Yes	Yes	Yes	Yes	No
24mm	Yes	Yes	Yes	Yes	No
25mm	Yes	Yes	Yes	Yes	No

Legacy Centerpulse Durasul[®] Polyethylene Head/Neck Length (all diameters)

00-7210-0XX-XX or 01.01012.XXX Catalog Numbers

Stem Diameter	-4mm	+0mm	+4mm	+8mm
14mm	Yes	Yes	Yes	No
15mm	Yes	Yes	Yes	No
16mm	Yes	Yes	Yes	Yes
17mm	Yes	Yes	Yes	Yes
18mm	Yes	Yes	Yes	Yes
19mm	Yes	Yes	Yes	Yes
20mm	Yes	Yes	Yes	Yes
21mm	Yes	Yes	Yes	Yes
22mm	Yes	Yes	Yes	Yes
23mm	Yes	Yes	Yes	Yes
24mm	Yes	Yes	Yes	Yes
25mm	Yes	Yes	Yes	Yes

BIOLOX Delta Head/Neck Length (all diameters)

00-8777-0XX-XX Catalog Numbers

Stem Diameter	-3mm	+0mm	+3.5mm	+7 mm
14mm	Yes	Yes	Yes	No
15mm	Yes	Yes	Yes	No
16mm	Yes	Yes	Yes	Yes
17mm	Yes	Yes	Yes	Yes
18mm	Yes	Yes	Yes	Yes
19mm	Yes	Yes	Yes	Yes
20mm	Yes	Yes	Yes	Yes
21mm	Yes	Yes	Yes	Yes
22mm	Yes	Yes	Yes	Yes
23mm	Yes	Yes	Yes	Yes
24mm	Yes	Yes	Yes	Yes
25mm	Yes	Yes	Yes	Yes

+ BIOLOX[®] is a trademark of CeramTec AG.

Insertion of the Stem

To insert the implant, securely attach the Impactor/Extractor making sure the keyed portion of the Impactor/Extractor is lined up with the keyed portion of the inserter feature on the implant and that the threads are fully engaged. If desired, the Positioning Bar (75.85.00) is threaded into the proximal lateral portion of the handle on the Impactor/Extractor. Note the orientation of the femoral neck of the stem in relationship to the position of the Positioning Bar to help assess femoral anteversion. There are also etched dotted lines running the length of the Impactor/Extractor to help assess the anteversion.

The stem is inserted into the medullary canal and driven into its definitive position with a few strikes of the mallet. The prosthesis should advance with each blow until the required stability has been achieved and the prosthesis no longer moves. Oftentimes, the sound of mallet blows change at the point of final seating. If the implant does not advance with each mallet blow, stop insertion and remove the component. Remove additional bone from the areas preventing full insertion and insert the component again. With the final femoral implant in place, assess the support of the femur and/or adjunct reinforcement. Any remaining cavities between the prosthesis and the surrounding cortical bone can be filled with bone chips.

Femoral Head Assembly

Once the implant is fully seated in the femoral canal, place the selected Femoral Head Provisional onto the taper of the implant. Perform a trial reduction to assess joint stability, range of motion, and restoration of leg length and offset.

When the appropriate femoral head implant is confirmed, remove the Femoral Head Provisional. Thoroughly clean and dry the taper on the femoral neck. Then place the selected femoral head on the taper and twist it slightly to secure it. Impact it by striking the Head Impactor with one sharp blow of the Mallet. Test the security of the head fixation by trying to remove it by hand.

Reduce the hip and assess leg length, range of motion, stability, and abductor tension.

Note: Always check that the neck taper and female taper of the femoral head are clean and dry before impaction. Also, do not impact the femoral head onto the taper before driving the prosthesis down the femoral canal as the femoral head may loosen during impaction of the implant.

Wound Closure

After obtaining hemostasis, insert a *Hemovac*® Wound Drainage Device, if desired. Then close the wound in layers.

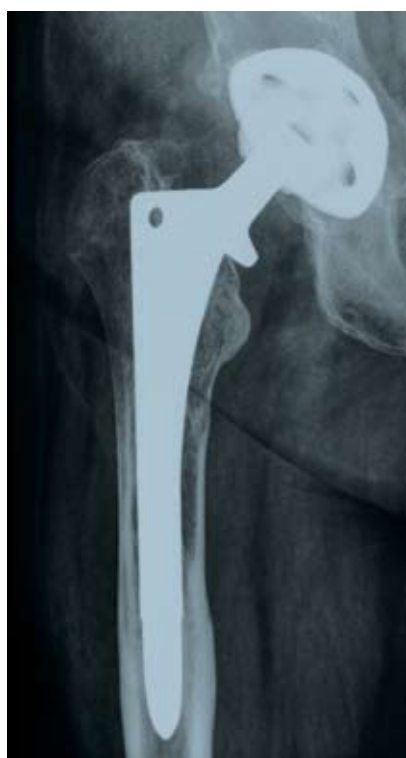Postoperative Management

The postoperative management of patients with *Wagner SL Revision Stems* is determined by the surgical technique, patient bone quality, patient activity level, fit of the implant, and the surgeon's judgment. Weight bearing after revision surgery requires more external support for a longer period due to the nature of the extensive surgery and bone disruption.

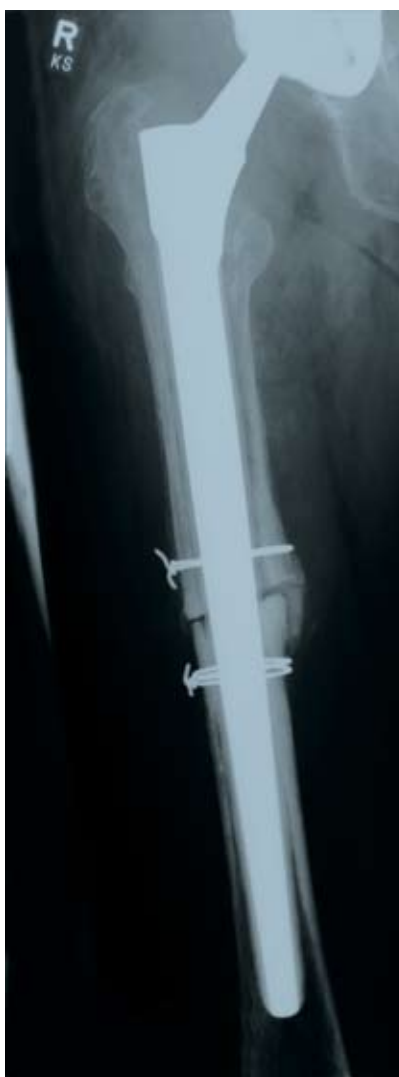Note: Accepted practices of postoperative care should be followed. The patient must be informed and made aware of the limitations of total joint reconstruction and the necessity of limiting weight and physical activity to protect the femoral stem from unnecessary stresses. In patients where proximal support was not achievable, additional risk may be present.

Case Studies

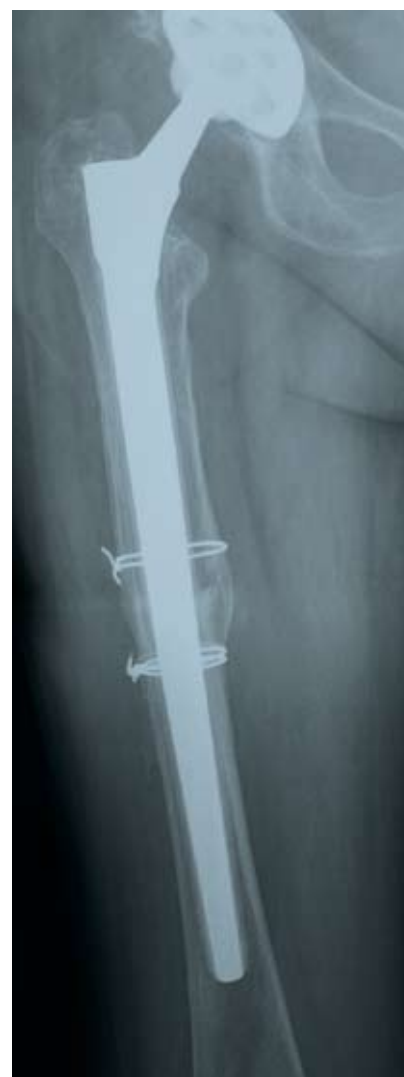Case Study Transfemoral Approach



Loosening of a cementless primary prosthesis implanted 8 years earlier in a 66-year-old woman. There is massive stress shielding and paper-thin cortical bone in the femur.

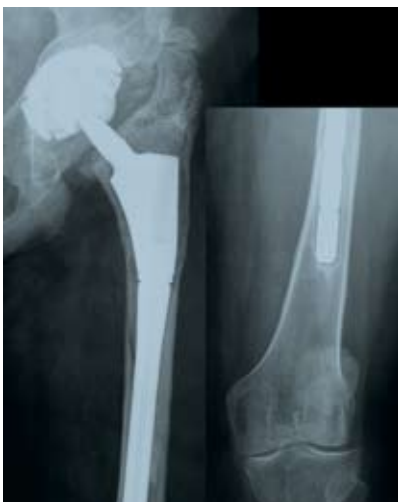

One year postoperative, after prosthesis exchange with a *Wagner SL Revision Stem* through a transfemoral approach.

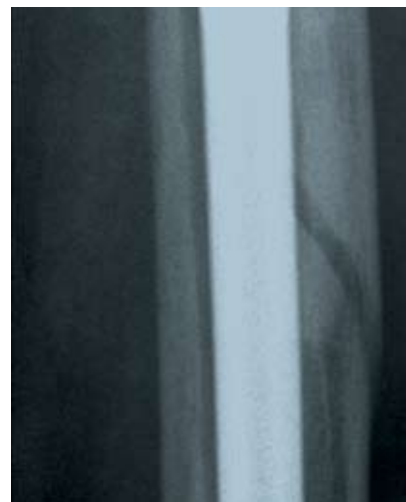

Two years postoperative: good consolidation of the transfemoral approach.

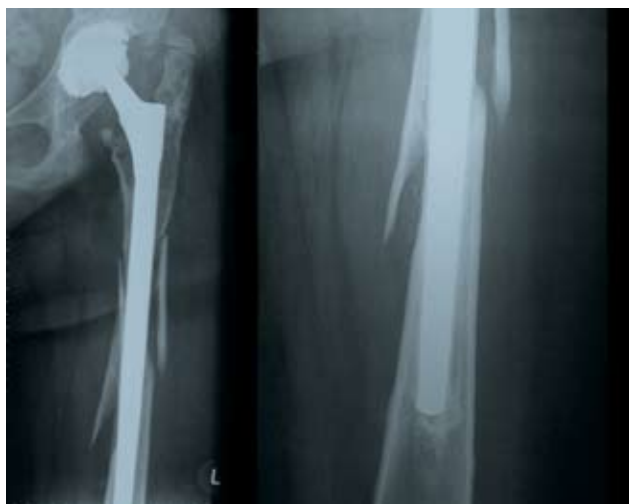Case Study Periprosthetic Fracture



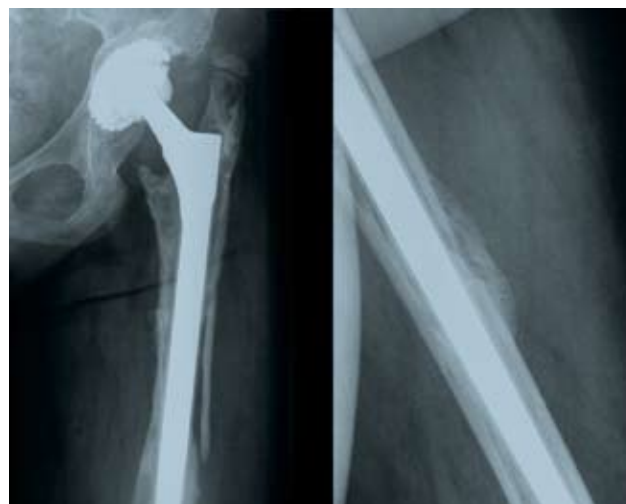Two years after implantation of a modular revision prosthesis, there was a considerable subsidence of the prosthesis with a leg shortening of 2.5 cm. A minor accident caused an extensive spiral fracture.



Detail of the spiral fracture. The remains of bone cement not removed after the earlier revision are also recognizable.

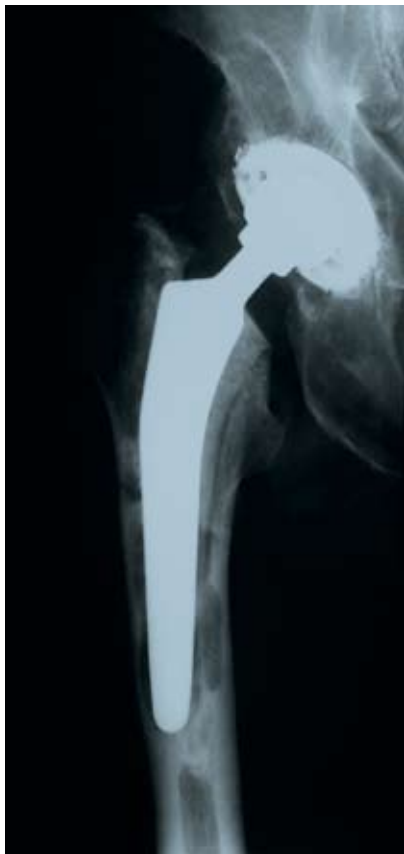

X-ray image 3 weeks postoperative. The fracture has been “threaded up” with a *Wagner SL Revision Stem* with very scant removal of soft tissue. The tip of the prosthesis is firmly anchored in the distal femur.

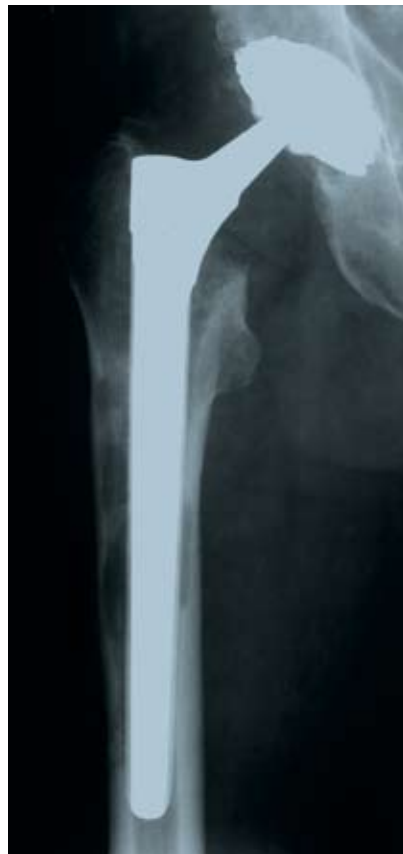

X-ray image 6 weeks postoperative. The fracture shows active callous formation. The patient has no complaints and in particular, no thigh pain is reported.

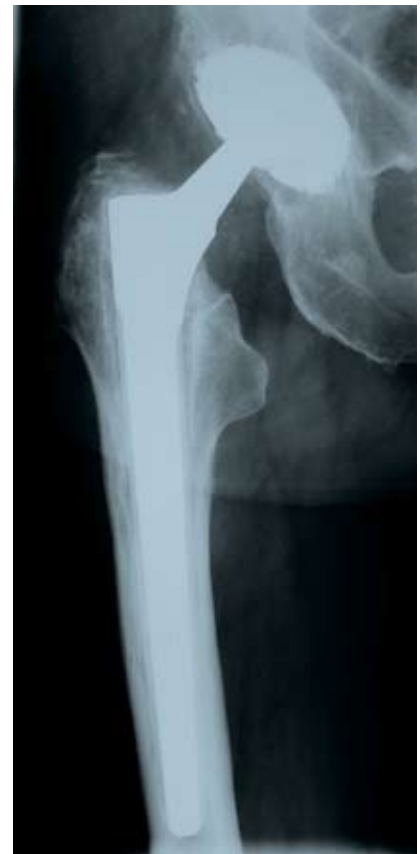Case Study Endofemoral Approach



61-year-old patient, 4 years after implantation of a cemented primary prosthesis. Chronic *Staphylococcus epidermidis* infection. Septic loosening with considerable osteolysis.

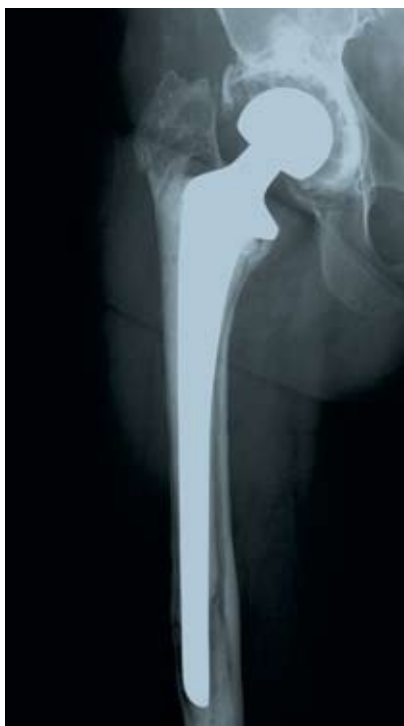

After 3 weeks: revision with endofemoral approach and radical debridement. No transplant at stem, only implantation of a *Wagner SL Revision Stem*.

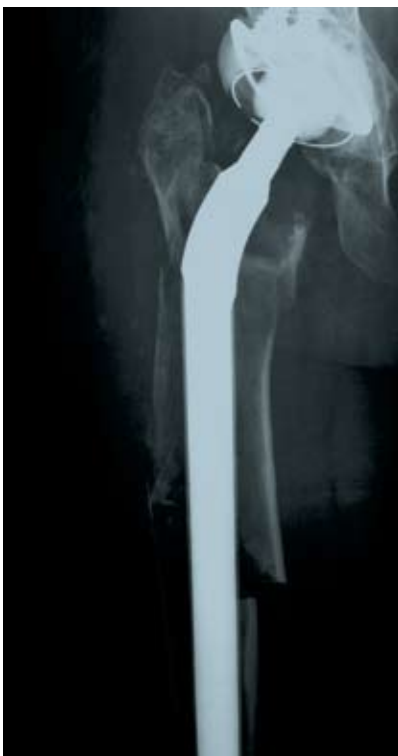

After one year, the defects have largely been filled. Normalization of laboratory parameters.

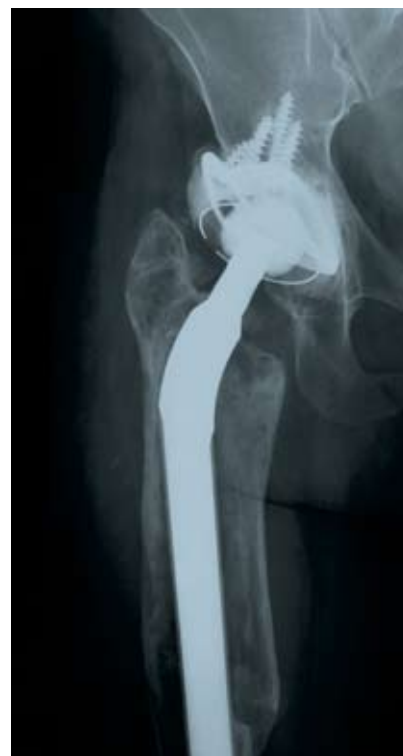Case Study Nine-Year Result



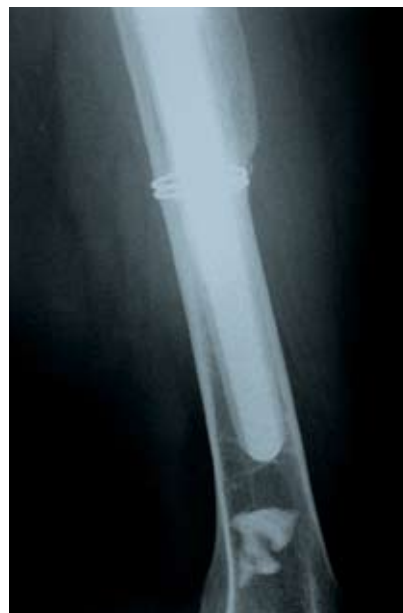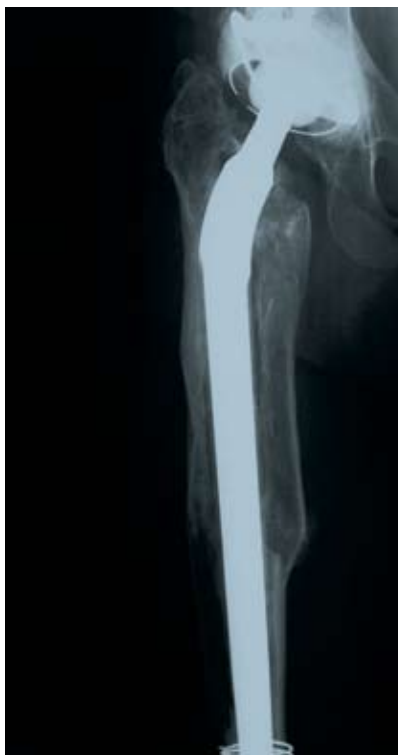58-year-old woman, 5 years after implantation of a long-stemmed cemented revision prosthesis. The prosthesis has migrated toward varus and has perforated the lateral cortical bone distally. The bone quality proximally is extraordinarily poor, which makes implantation of a short stem prosthesis impossible.



Three weeks after implantation of a *Wagner SL Revision Stem* of the earlier generation by a transfemoral approach. The thin cortical bone permitted no osteosynthesis of the bone flap.

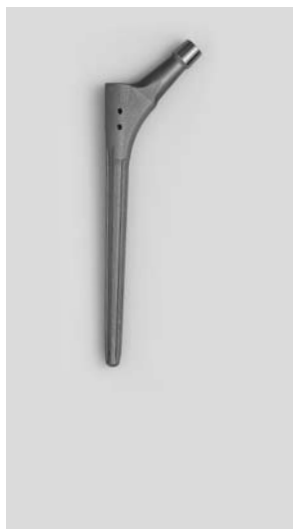

Six months postoperative the bone flap shows the beginning of bone healing. The soft tissue tension of the thigh muscles has pressed the bony shell onto the implant.



Nine years postoperative there has been further recovery of the bone. As a sure radiological sign of osseointegration there are strong bony bridges at the tip of the prosthesis.

Implants

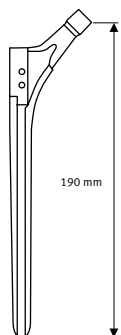


Wagner SL Revision Stem
190 mm

Details
Taper 12/14
Uncemented

Ti6Al7Nb
Protasul-100

STERILE R

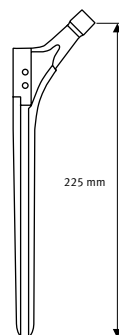


Wagner SL Revision Stem
225 mm

Details
Taper 12/14
Uncemented

Ti6Al7Nb
Protasul-100

STERILE R

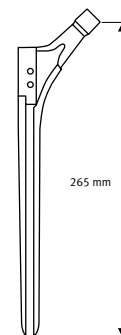


Wagner SL Revision Stem
265 mm

Details
Taper 12/14
Uncemented

Ti6Al7Nb
Protasul-100

STERILE R

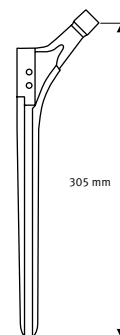


Wagner SL Revision Stem
305 mm

Details
Taper 12/14
Uncemented

Ti6Al7Nb
Protasul-100

STERILE R



ø mm	REF
14	01.00101.914*
15	01.00101.915*
16	01.00101.916
17	01.00101.917
18	01.00101.918
19	01.00101.919
20	01.00101.920

ø mm	REF
14	01.00102.214*
15	01.00102.215*
16	01.00102.216
17	01.00102.217
18	01.00102.218
19	01.00102.219
20	01.00102.220
21	01.00102.221
22	01.00102.222

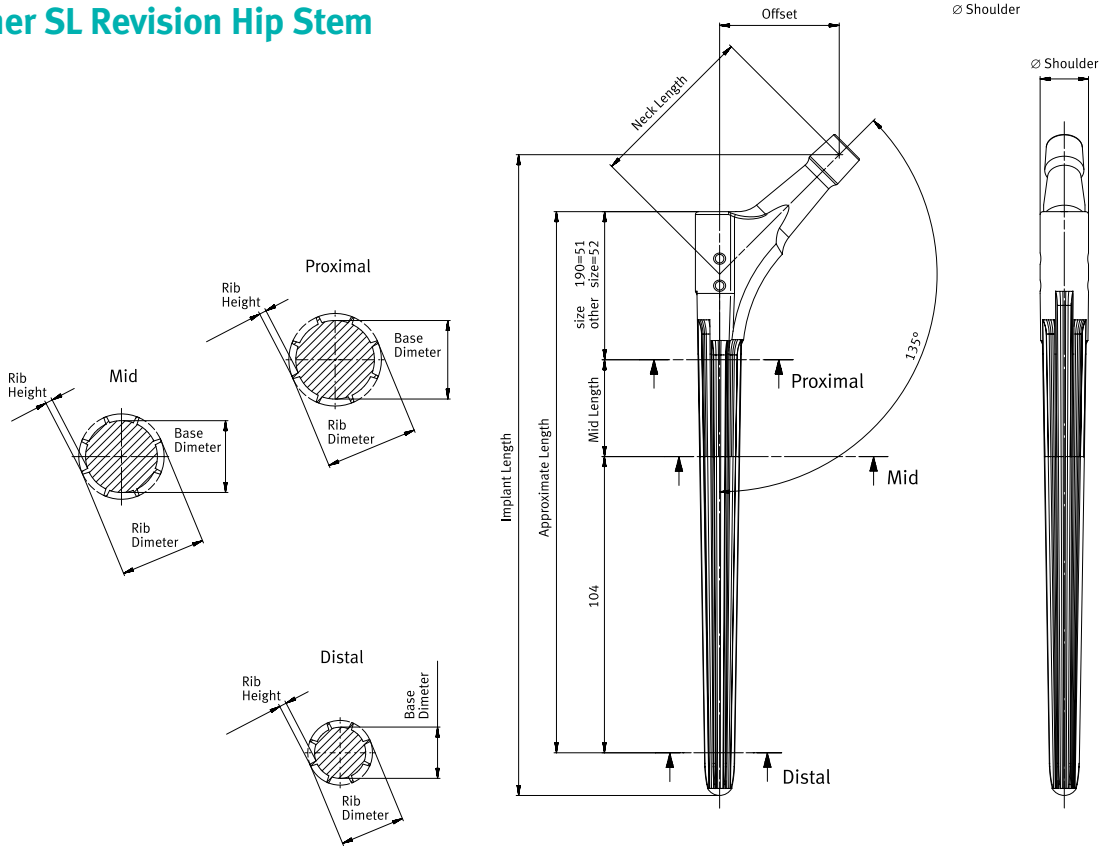
ø mm	REF
14	01.00102.614*
15	01.00102.615*
16	01.00102.616
17	01.00102.617
18	01.00102.618
19	01.00102.619
20	01.00102.620
21	01.00102.621
22	01.00102.622
23	01.00102.623
24	01.00102.624
25	01.00102.625

ø mm	REF
14	01.00103.014*
15	01.00103.015*
16	01.00103.016
17	01.00103.017
18	01.00103.018
19	01.00103.019
20	01.00103.020
21	01.00103.021
22	01.00103.022
23	01.00103.023
24	01.00103.024
25	01.00103.025

* Do not use with femoral heads longer than L (+4 mm)

Lengths of 345 mm (34.00.79.XXX) are available on request and only with the neck angle of 145°. Impactor/extractor and slot hammer for these selections are also only available by request.

Wagner SL Revision Hip Stem

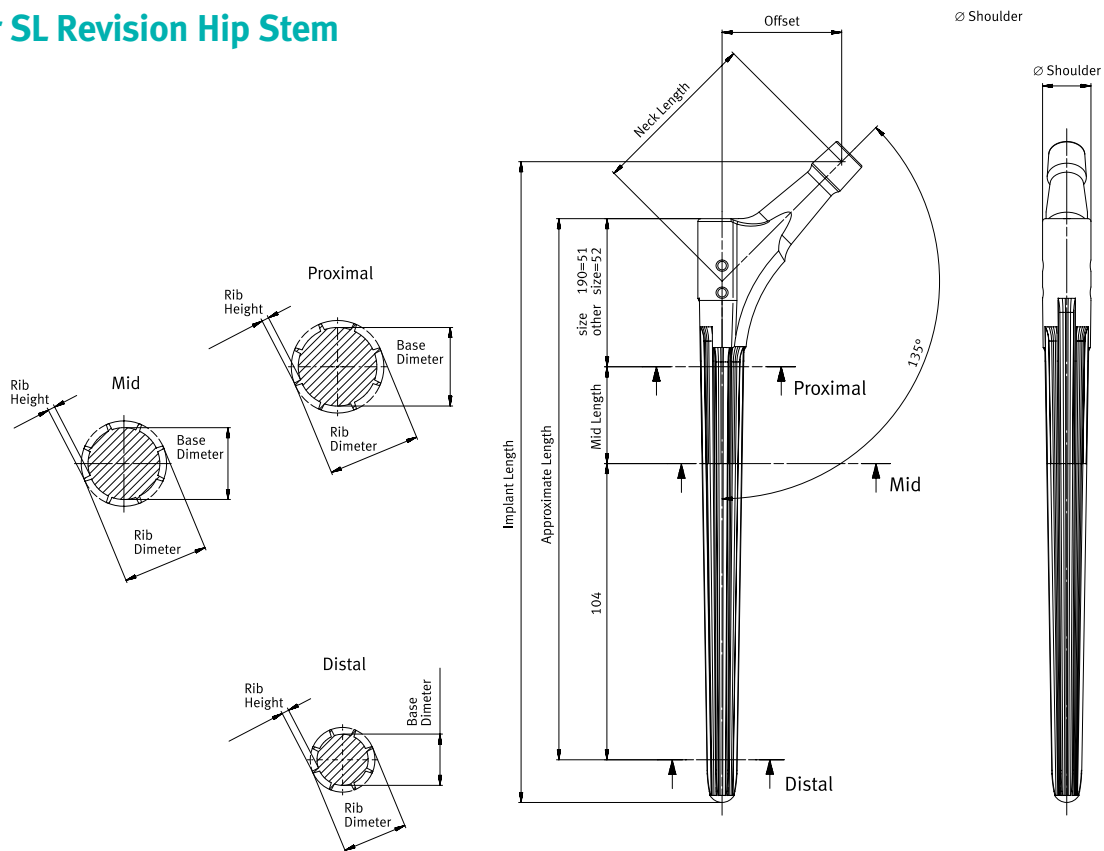


Midshaft Section (mm)

Distal Section (mm)

Size	Rib Height			Base Diameter			Rib Diameter			Rib Height			Base Diameter			Shoulder		
	225	265	305	190	225	265/305	190	225	265/305	190	225	265/305	190	225	265/305	190	225	265/305
14	1	12	12	12	10.37	10.37	10.4	1	8.4	8.4	8.4	15.75	17	17				
15	1.2	12.6	12.6	12.6	11.37	11.37	10.4	1.2	9.0	9.0	9.0	16.75	17	17				
16	1.3	13.4	13.4	13.4	12.37	12.37	10.4	1.3	9.8	9.8	9.8	17	17	17				
17	1.5	14	14	14	13.37	13.37	10.4	1.5	10.4	10.4	10.4	17	17	17				
18	1.6	14.8	14.8	14.8	14.37	14.37	14.4	1.6	11.2	11.2	11.2	19.74	21	21				
19	2	15	15	15	15.37	15.37	15.4	2.4	10.5	10.5	10.5	20.75	21	21				
20	2	16	16	16	16.37	16.37	16.4	2.9	10.6	10.6	10.6	21	21	21				
21	2	-	17	17	-	17.37	17.4	2.9	-	11.6	11.6	-	21	21				
22	2	-	18	18	-	18.37	18.4	2.9	-	12.6	12.6	-	25	25				
23	2	-	19	19	-	-	19.4	2.9	-	-	13.6	-	-	25				
24	2	-	20	20	-	-	20.4	2.9	-	-	14.6	-	-	25				
25	2	-	21	21	-	-	21.4	2.9	-	-	15.6	-	-	25				

Wagner SL Revision Hip Stem



Distal Section (mm)

Size	Offset/Neck Length (mm)			Rib Diameter				Rib Height	Base Diameter				Midshaft Length			
	190	225	265/305	190	225	265	305		190	225	265	305	190	225	265	305
14	42/59.4	42/59.4	42/59.4	14	15.37	16.58	17	1	12	13.37	14.58	15	0	34	74	114
15	42/59.4	42/59.4	42/59.4	15	16.19	17	17	1.2	12.6	13.79	14.6	14.6	0	34	74	114
16	42/59.4	42/59.4	42/59.4	16	17	17	17	1.3	13.4	14.4	14.4	14.4	0	34	74	114
17	42/59.4	42/59.4	42/59.4	17	17	17	17	1.5	14	14	14	14	0	34	74	114
18	44/62.2	44/62.2	44/64.2	18	19.37	20.58	21	1.6	14.8	16.17	17.38	17.8	0	34	74	114
19	44/62.2	44/62.2	44/64.2	19	20.19	21	21	2	15	16.19	17	17	0	34	74	114
20	44/62.2	44/62.2	44/64.2	20	20	21	21	2	16	17	17	17	0	34	74	114
21	-	44/62.2	44/64.2	-	21	21	21	2	-	17	17	17	-	34	74	114
22	-	46/65.0	46/65.0	-	23.37	24.58	25	2	-	19.37	20.58	21	-	34	74	114
23	-	-	46/65.0	-	-	25	25	2	-	-	21	21	-	-	74	114
24	-	-	46/65.0	-	-	25	25	2	-	-	21	21	-	-	74	114
25	-	-	46/65.0	-	-	25	25	2	-	-	21	21	-	-	74	114

Instruments



Tray basic instruments and reamers (complete)

REF
ZS01.00109.000

Tray basic instruments (empty)

REF
01.00109.031

Tray insert basic instruments (empty)

REF
01.00109.032

Tray reamers (empty)

REF
01.00109.033

Tray insert reamers (empty)

REF
01.00109.034

Standard cover, gray

REF
01.00029.031



Reamers*

ø mm	REF
14	01.00109.014
15	01.00109.015
16	01.00109.016
17	01.00109.017
18	01.00109.018
19	01.00109.019
20	01.00109.020
21	01.00109.021
22	01.00109.022
23	01.00109.023
24	01.00109.024
25	01.00109.025



Ruler, long

mm	REF
300	75.11.30



Osteotome, straight

Size in mm	REF
4x10	75.11.45-10
5x15	75.11.45-15
5x20	75.11.45-20



Impactor and positioning bar

	REF
Impactor	01.00109.808
Positioning bar	75.85.00



Extractor connector for slap hammer REF 01.00129.190

	REF
	01.00109.801



Handle with quick coupling


	REF
	75.00.25



Impactor consisting of:

	REF
Handle	75.11.00-02
Synthetic top	75.11.00-03

* The new reamers (01.00109.014–025) must under no circumstances be mixed with the old awl (75.11.00-140–205).



Tray trial stems (complete)	REF	ZS01.00109.100
Tray trial stems (empty)	REF	01.00109.110
Standard cover, gray	REF	01.00029.031



Trial stems, distal

ø mm	REF
14	01.00109.114
15	01.00109.115
16	01.00109.116
17	01.00109.117
18	01.00109.118
19	01.00109.119
20	01.00109.120
21	01.00109.121
22	01.00109.122
23	01.00109.123
24	01.00109.124
25	01.00109.125



Screws for proximal part

mm	REF
190	01.00109.809
225	01.00109.805
265	01.00109.806
305	01.00109.807



Hex wrench

mm	REF
3,5	79.15.84



Trial stems, proximal

mm	REF
190	01.00109.810
225	01.00109.802
265	01.00109.803
305	01.00109.804

Contact your Zimmer representative or visit us at www.zimmer.com



+H124970102002001/\$090316R1C09J