

Reliability of Diagnosis of Acetabular Dysplasia with Tomosynthesis

Department of Orthopaedic Surgery, Juntendo University

Hironori Ochi, Tomonori Baba, Hiroki Tanabe, Sammy Banno, Yu Ozaki,
Yasuhiro Homma, Taiji Watari, Mikio Matsumoto, Hideo Kobayashi and Kazuo Kaneko

1. Introduction

Acetabular dysplasia that concentrates the joint contact pressure distribution can result in cartilage degeneration. An accurate evaluation of acetabular coverage is important in cases of acetabular dysplasia, as diagnosis and treatment methods differ depending on the degree of coverage. However, diagnostic criteria for acetabular dysplasia can depend on the radiography method and limb position used for evaluation, and are not always equivalent.^{1),2)} Tomosynthesis is a radiographic technique that can be used with a variety of body and limb positions including upright or supine and that produces multiple tomographic images from a single acquisition, which therefore allows a more detailed evaluation of the bone trabecular structure³⁾ (Fig. 1).




Fig.1 Shimadzu SONIALVISION G4 R/F System
This system can perform tomosynthesis with the patient upright position.

2. Objective

The objective of this study was to compare the reliability of diagnosing acetabular dysplasia when using radiography images (Xp) and tomosynthesis images.

3. Subjects and Methods

This study investigated 54 hip joints of 27 patients diagnosed with acetabular dysplasia following examination at this hospital between December 2016 and September 2017, and analyzed 49 hip joints with a center-edge angle (CEA) of under 25° according to radiography images. Subjects included 3 males and 24 females with an overall mean age of 42.6 years (20–56). Five hip joints with a CEA of $\geq 25^\circ$ on radiography images were excluded from analysis. Other exclusion criteria were a KL classification of grade 2 or higher osteoarthritis, a history of hip joint surgery, and rheumatoid arthritis or any other inflammatory disorder, though no subjects met these criteria.

The body and leg position used for radiography were upright and 15° internal rotation, respectively. Radiography images of the front view of the hip joint were obtained on a general radiography system, and tomosynthesis images were obtained with Shimadzu SONIALVISION G4. CEA, Sharp angle (SA), and Acetabular roof obliquity (ARO) are angles used to evaluate acetabular dysplasia, and were the

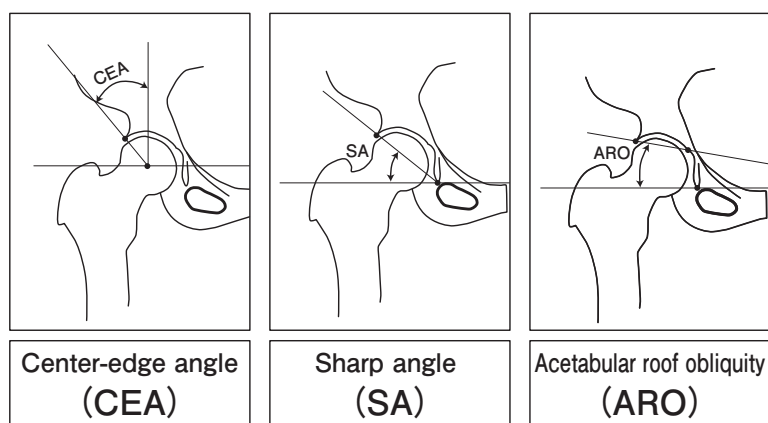


Fig.2 Angles Used to Evaluate Acetabular Dysplasia (CEA, SA and ARO)²⁾

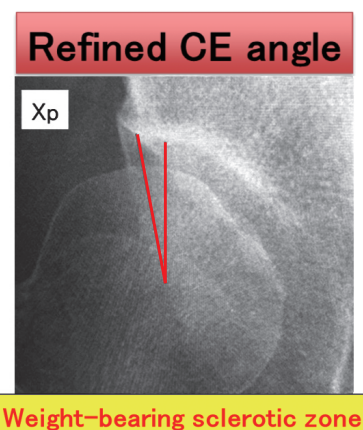


Fig.3 Refined CEA of Ogata et al.⁵⁾

parameters investigated in this study²⁾ (Fig. 2). These angles were measured by determining the weight-bearing sclerotic zone then measuring the Refined CEA according to Ogata et al.⁵⁾ (Fig. 3).

Statistical analysis was performed with JMP software package version 11.2 (SAS Institute, Cary, NC, USA). A paired t-test was used to compare radiography images and tomosynthesis images, and intra-rater and inter-rater concordance rates (Interclass Correlation Coefficient [ICC]) were calculated. $p < 0.05$ was considered significant.

4. Results

The mean and standard deviation statistics for CEA, SA and ARO measured using radiography images and tomosynthesis images are shown in Table 1. Tomosynthesis CEA was significantly larger, and tomosynthesis SA was significantly smaller than measured using radiography. The intra-rater concordance and inter-rater concordance rates of the three angles are also shown in Table 2.

Table.1 CEA, SA and ARO measured using Radiography and Tomosynthesis

Comparison of Xp and Tomosynthesis				
	Xp	Tomo	Difference (Xp-Tomo)	P value
CEA	13.2 (6.3)	16.8 (7.1)	-3.6 (3.6)	0.0085
SA	47.1 (3.4)	45.7 (3.5)	1.4 (1.5)	0.047
ARO	16.2 (6.0)	15.6 (6.6)	0.59 (3.3)	0.64

Mean
(Standard deviation)

Table.2 Intra-Rater and Inter-Rater Concordance Rates for CEA, SA and ARO⁴⁾

Intra-rater concordance rates			Inter-rater concordance rates		
	Xp (ICC)	Tomo (ICC)		Xp (ICC)	Tomo (ICC)
CEA	0.90	0.87	CEA	0.87	0.86
SA	0.74	0.79	SA	0.91	0.82
ARO	0.87	0.87	ARO	0.87	0.92

ICC

0.00–0.20, slight
0.21–0.40, fair
0.41–0.60, moderate
0.61–0.80, substantial
0.81–1.00, almost perfect

5. Discussion

A comparison of this study and a previous report on radiography methods used for diagnostic imaging of acetabular dysplasia is shown in Fig. 4. Chadayammuri et al. compared CEA obtained by radiography and CT images, and reported that CT images showed significantly larger than radiography in Hip dysplasia (acetabular dysplasia) and Cam-type FAI (Femoroacetabular Impingement). This difference arose because Refined CEA of Ogata et al. was measured by radiography (supine) and Classic CEA of Wiberg was measured by CT images (supine).^{2),6)} In the meantime, tomosynthesis can be used to acquire tomographic images in an upright position, and tomosynthesis allows for the detailed evaluation of the load plane of the acetabular cover. The reason for the significant difference in CEA and SA observed in this study is considered to be that tomosynthesis allowed a more accurate measurement of the lateral acetabular rim, which is the load plane of the acetabulum, compared to radiography.

The limitations of this study are that no investigation was performed into a relationship with symptoms, and no comparison was made with CT, MRI or other image-based evaluation methods.

6. Conclusion

Tomosynthesis allowed a more detailed diagnosis of acetabular dysplasia in an upright position compared to radiography. Tomosynthesis can potentially be applied in diagnostic imaging of acetabular dysplasia to help in determining a treatment plan.

References

- Heijboer et al. Osteoarthritis and cartilage 2013
- Chadayammuri et al. Journal of hip preservation surgery 2015
- Tang et al. Skeletal radiology 2016
- Lee et al. Archives of orthopaedic and trauma surgery 2011
- Ogata et al. J Bone Joint Surg Br 1990
- Wiberg et al. Acta Chir Scand 1939

Chadayammuri et al(2015)		Xp	CT	Difference (Xp-CT)	P value
Hip dysplasia	CEA	17.5 (1.9)	22.6 (4.0)	-4.9	<0.001
Cam-type FAI with concomitant hip dysplasia		17.3 (4.0)	22.8 (3.2)	-5.5	0.011

Xp: Refined CEA

CT: Classic CEA

Weight-bearing sclerotic zone not being measured.
Limb position for radiography:
evaluated supine in non-weight-bearing position

This study		Xp	Tomo	Difference (Xp-Tomo)	P value
Hip dysplasia	CEA	13.2 (6.3)	16.8 (7.1)	-3.6 (3.6)	0.0085

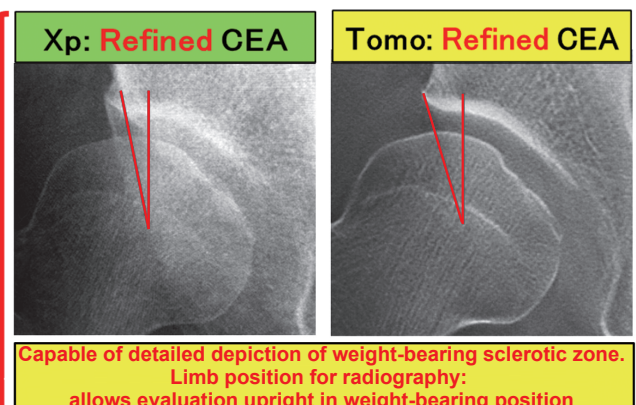


Fig.4 Comparison of this Study and a Previous Report on Radiography Methods for Diagnostic Imaging of Acetabular Dysplasia^{2),6)}